

Molina Clinical Policy

Sclerotherapy and Adhesive Ablation for Varicose Veins:

Policy No. 431

Last Approval: 4/10/2024

Next Review Due By: April 2025



DISCLAIMER

This Molina Clinical Policy (MCP) is intended to facilitate the Utilization Management process. Policies are not a supplementation or recommendation for treatment; Providers are solely responsible for the diagnosis, treatment, and clinical recommendations for the Member. It expresses Molina's determination as to whether certain services or supplies are medically necessary, experimental, investigational, or cosmetic for purposes of determining appropriateness of payment. The conclusion that a particular service or supply is medically necessary does not constitute a representation or warranty that this service or supply is covered (e.g., will be paid for by Molina) for a particular Member. The Member's benefit plan determines coverage – each benefit plan defines which services are covered, which are excluded, and which are subject to dollar caps or other limits. Members and their Providers will need to consult the Member's benefit plan to determine if there are any exclusion(s) or other benefit limitations applicable to this service or supply. If there is a discrepancy between this policy and a Member's plan of benefits, the benefits plan will govern. In addition, coverage may be mandated by applicable legal requirements of a State, the Federal government or CMS for Medicare and Medicaid Members. CMS's Coverage Database can be found on the CMS website. The coverage directive(s) and criteria from an existing National Coverage Determination (NCD) or Local Coverage Determination (LCD) will supersede the contents of this MCP and provide the directive for all Medicare members. References included were accurate at the time of policy approval and publication.

OVERVIEW

This policy addresses sclerotherapy for the treatment of symptomatic varicose veins of the lower extremity.

Varicose veins are a form of venous insufficiency characterized by dilated, elongated, or tortuous veins caused by permanent valvular inefficiency and commonly affect the main axial superficial veins (the great saphenous vein [GSV] and the small saphenous vein [SSV] or their superficial tributaries) in the lower extremities (Raetz et al. 2019). Varicose veins are clinically defined as subcutaneous veins dilated to at least 3 mm in diameter and are part of a continuum of chronic venous disorders which range from fine telangiectasias, or spider veins (less than 1 mm); and reticular veins (1 to 3 mm) to chronic venous insufficiency (Raetz et al. 2019). The underlying cause of most varicose veins is cited as primary valvular insufficiency resulting in valvular reflux with only about 5 to 20% of varicose veins occurring secondary to conditions, such as deep vein thrombosis (DVT), pelvic tumor or arteriovenous fistula (Swoboda et al. 2018). Risk factors include family history of venous disease; female sex; older age; chronically increased intra-abdominal pressure due to obesity, pregnancy, chronic constipation, or a tumor; prolonged standing; DVT causing damage to valves and secondary revascularization; and arteriovenous shunting. Varicose veins affect up to 30% of the general population, with rates notably higher in the elderly and more women affected than men (Antani and Dattilo, 2023). The clinical presentation can range from asymptomatic to localized symptoms at the varicose vein site, which can be unilateral or bilateral. Most varicose veins are primarily an aesthetic concern and do not necessitate medical intervention; however, in some circumstances, circulation may be compromised sufficiently to cause pain, aching, heaviness, cramping, throbbing, restlessness, and swelling. Major complications of more serious underlying vascular insufficiency may lead to infection, superficial thrombophlebitis, venous ulceration, subcutaneous tissue loss, lipodermatosclerosis, and in rare cases perforation of a varicose vein has caused significant external hemorrhage (Raetz et al., 2019). Conservative measures for symptomatic varicose veins of the legs include compression hosiery, lifestyle modifications, such as reduced standing activity, elevating the legs, and weight management. Interventional therapies in cases with severe discomfort, ulceration, or thrombosis include surgical ligation and excision (vein stripping) or minimally invasive procedures (sclerotherapy, endovenous laser ablation, radiofrequency ablation [RFA]).

Sclerotherapy (endovenous chemical ablation) is the targeted chemical ablation of a varicose vein by intravenous injection of a liquid or foam sclerosant. The procedure involves injection of sclerosant into vein to cause a thrombophlebitic reaction that fibroses and occludes the vein; over time, the affected vein transforms into a thread of fibrous connective tissue and is absorbed by the body. However, varicose veins can recannulate. Possible complications of sclerotherapy include formation of blood clots, skin staining, inflammation, ulcers and tissue damage and reactions to the sclerosing agent (Tisi et al.). Sclerotherapy may be used for symptomatic varicosities in various anatomic locations as well as vessels that present only a cosmetic problem. Polidocanol, sodium tetradecyl sulfate, hypertonic saline, and glycerin are the most used sclerotherapy agents in the treatment of chronic venous disease in the lower extremities. Only polidocanol and sodium tetradecyl sulfate are approved in the United States for this indication (Scovell 2024).

Diagnosis may be made clinically by a finding of varicosity ≥ 3 mm on a physical exam. Several ultrasound technologies are utilized in conjunction with other noninvasive testing since a physical examination alone may not be sufficient to detect the physiological properties of the varicosities (Mathes 2023). Varicose veins may be diagnosed

Molina Clinical Policy

Sclerotherapy and Adhesive Ablation for Varicose Veins:

Policy No. 431

Last Approval: 4/10/2024

Next Review Due By: April 2025



using Duplex ultrasonography, Doppler ultrasound, or plethysmography. Duplex ultrasound (performed by a qualified physician or technologist supervised by a qualified physician) is the standard for assessing venous disease in the lower limb and or diagnosis of superficial venous incompetence. It is often utilized to in the pre-operative phase by mapping all varicose veins, tributaries, and incompetent perforating veins. Following the initial vein mapping, it is usually not necessary to perform follow-up scanning for subsequent treatment sessions. In the published medical literature, it has not been proven that repeat Duplex or Doppler studies are necessary for the effective outcome of the treatment when performed as part of a series of sclerotherapy procedures. Furthermore, routine use of any of these devices is not deemed as medically necessary in the absence of venous symptoms or clinical evidence of venous insufficiency or reflux. Photographs or diagrams are useful in determining the size and extent of the varicosities. The CEAP (Clinical [C], Etiological [E], Anatomical [A] and Pathophysiological [P]) classification is an internationally recognized classification system based on clinical manifestations of chronic venous disorders, on current understanding of the etiology, the involved anatomy, and the underlying venous pathology that results from venous reflux (Lurie et al. 2020) (refer to 'Supplemental Information' section for additional information of CEAP classification).

The evaluation of a patient with lower extremity venous incompetence and its advanced consequences—edema and skin changes—should include the assessment of history and physical examination including the CEAP classification and revised Venous Clinical Severity Score (VCSS). A duplex ultrasound scan of the deep and superficial venous systems must support the examination findings (Evolent 2024).

Treatment. If chronic venous disease is suspected as the cause of symptoms in the lower extremities after a comprehensive history and physical is performed, a trial of conservative measures for three months, including elevation, analgesics, graded compression stockings, and skin or wound care if needed may be successful in treating symptoms, especially healing venous ulcers. If symptoms persist, and reflux of ≥ 500 milliseconds (ms) in the saphenous veins is documented by venous duplex ultrasound, interventional treatment is recommended for chronic venous disease with CEAP classification of C2 or higher (De Maeseneer et al. 2022; American Vein and Lymphatic Society 2016). C2 corresponding to a clinical classification of varicose veins (≥ 3 mm) (Raetz 2019). When venous ulcers are present, interventional treatment along with continuation of compression therapy is recommended to decrease recurrence.

Types of Sclerosing Agents

1. Hyperosmolar agents cause nonspecific cellular destruction, burning, affects RBCs- dehydration (e.g., hypertonic saline usually mixed with Lidocaine).
2. Detergent's cause cell surface disruption and extraction of proteins within seconds, lasting hours. Examples include Glycerin with Lidocaine and Epinephrine, Polidocanol (Asclera, Varithena, Sodium tetradecyl sulfate).
3. Chemical agents cause direct corrosive effect, disrupts the intercellular cement, poisons cell surface proteins, and affects chemical bonds immediately on vein wall exposure. Sklermo or Chromex is a chemical agent and is not FDA approved for this procedure.

Ultrasound guided sclerotherapy (UGS), also known as echosclerotherapy (also called aimed sclerotherapy or sonographic sclerotherapy) utilizes ultrasound to guide the injections and enhance the precision of the therapy. This technique is primarily used for treatment of veins below the surface, such as deep veins and other varices that are difficult to visualize. Sclerotherapy is performed using either a liquid or "foamed" sclerosant, as determined by the physician's clinical judgment, while the vein is monitored via ultrasound (Society for Vascular Surgery/American Venous Forum). This allows for the treatment of veins that are not visible because they are beneath the skin's surface and would otherwise require surgical removal. A needle is guided into the abnormal vein using ultrasound to deliver medication that obliterates the lining of the blood vessel, causing it to collapse and seal shut.

Liquid Sclerosant is often used to treat cosmetic telangiectasias and reticular veins. Liquid sclerotherapy is also of value in addressing bleeding telangiectasias and for select cases of large vein treatment where unique individual features suggest liquid may be a safer option. FDA-approved liquid sclerosing agents include sodium tetradecyl sulfate and polidocanol.

Foam Sclerosant (Ultrasound-Guided Foam Sclerotherapy) is performed under ultrasound guidance for treatment of primary and recurrent varicose veins, including the distal GSV and SSV, perforating veins, and venous malformations. There are different types of foam: physician-compounded foam and non-compounded foam. Foam sclerotherapy is performed by mixing the liquid sclerosant agent with air. Varithena™ is the proprietary, commercially

Molina Clinical Policy

Sclerotherapy and Adhesive Ablation for Varicose Veins:

Policy No. 431

Last Approval: 4/10/2024
Next Review Due By: April 2025



available microfoam sclerosant with a polidocanol endovenous microfoam (PEM) combination product that dispenses a liquid sclerosant and low nitrogen gas under pressure from a proprietary canister and theoretically produces foam of consistent density with bubbles of more uniform diameter, making it more cohesive than physician-compounded sclerosant foam.

Regulatory Status

UGS for varicose veins is a procedure and thus not regulated by the U.S. Food and Drug Administration (FDA). However, medical devices, medications, or tests utilized as part of this procedure may be subject to FDA approval. The following have received FDA marketing clearance for the endovenous treatment of superficial vein reflux:

- Sodium Tetradecyl Sulfate Injection (sotradecol): Treatment of small, uncomplicated varicose veins of the lower extremities that show simple dilation with competent valves [FDA Approved November 12, 2004].
- Polidocanol
 - Asclera: Treatment of uncomplicated spider veins (varicose veins 1 mm or less in diameter) and uncomplicated reticular veins (varicose veins 1 to 3 mm in diameter) in the lower extremity [FDA approved March 30, 2010].
 - Varithena (PEM 1%) is a sclerosant microfoam for the treatment of incompetent great saphenous vein, accessory saphenous veins, and visible varicosities of the GSV system above and below the knee [FDA approved, November 25, 2013].

Compounded drug products are not FDA-approved and have not undergone FDA premarket review for safety, effectiveness, and quality.

RELATED POLICIES

Refer to MCG for other procedures related to varicose veins.

COVERAGE POLICY

Coverage for varicose vein treatment varies by plan and details regarding coverage details. Refer to the member's plan for specific information on benefits and coverage. The following coverage conditions apply if coverage is available for the treatment of varicose veins.

Sclerotherapy for the treatment of symptomatic varicose veins or tributaries may be authorized when **ALL** the following criteria are met:

1. Member meets **ONE** of the following with documentation of failure of compression therapy for **90 days** except in presence of non-healing ulcers.
 - a. Liquid Sclerotherapy of C1 (telangiectasias or reticular veins less than 3 mm) in presence of spontaneous and/or traumatic venous bleeding. The presence of reflux is not required for feeding reticular veins.
 - b. Foam or Liquid Sclerotherapy for incompetent symptomatic [C2: simple varicose veins (3 or larger) and VCSS greater than 6 or *C3-6] tributary/reticular veins (greater than or equal to 3mm) and/or GSV (greater than or equal to 5mm) and/or SSV (greater than or equal to 3mm) and with reflux duration greater than or equal to 500ms.
 - *C 3 - Ankle edema of venous origin (not foot edema)
 - C 4a - Skin pigmentation or eczema
 - C 4b - Lipodermatosclerosis or atrophic blanche
 - C 5 - Healed venous ulcer
 - C 6 - Open venous ulcer
 - c. Foam or Liquid Sclerotherapy in primary or recurrent GSV, SSV or Accessory/Tributary varicose veins, C2 [Simple varicose veins (3 or larger)], VCSS less than 6, tributary/reticular veins (greater than or equal to 3mm)

Molina Clinical Policy
Sclerotherapy and Adhesive Ablation for Varicose Veins:
Policy No. 431

Last Approval: 4/10/2024
Next Review Due By: April 2025



and/or GSV (greater than or equal to 5mm) and/or SSV (greater than or equal to 3mm) and with reflux duration greater than or equal to 500ms.

- d. Foam Sclerotherapy for incompetent perforator vein(s) demonstrating reflux greater than 500ms and diameter greater than 3.5mm when there is an active/old healed venous ulcer
- e. Foam or Liquid Sclerotherapy for large venous plexus or malformation demonstrating reflux greater than 500ms and diameter greater than 3mm in size.

NOTE: A complete Venous Duplex after each venous intervention is preferred to demonstrate the result of intervention on the intervened vein(s) and presence of reflux on target vein(s) of the same extremity.

2. ALL of the following documentation must be submitted:

- a. Failure of compression therapy for 90 days.
- b. Progress note that prompted the request (including symptoms, history and physical, CEAP, VCSS).
- c. Latest venous duplex report supporting request describing reflux (location and duration of reflux) and anatomy of veins with CEAP classification and VCSS score.
- d. Prior venous intervention report.
- e. For members with thrombophlebitis, dermatitis, ulcers or bleeding, pretreatment photographs of varicose veins are required to document the functional impairment. The photographs should accurately depict the clinical extent. Photographs are not required when pain is the only functional impairment.
- f. Other relevant supporting clinical documentation or rationale as requested by the Molina Clinical Reviewer.

** Reflux duration for GSV, SSV or accessory saphenous veins is greater than or equal to 0.5 seconds. Reflux duration for perforator veins must be greater than 0.35 seconds.*

***Refer to Supplemental Information for additional definitions, classifications, and scores.**

LIMITATIONS AND EXCLUSIONS

The following are considered **experimental, investigational, and unproven** based on insufficient evidence:

- 1. The treatment of CEAP clinical classification C0 (no visible or palpable signs of venous disease) is considered cosmetic, and therefore, not reasonable, and necessary for the purposes of Medicare coverage.
- 2. The treatment of CEAP clinical classification C1 (telangiectasias or reticular veins less than 3 mm) will be considered cosmetic, and therefore, not reasonable, and necessary for the purposes of Medicare coverage except in patients with spontaneous and/or traumatic venous hemorrhage.
- 3. Any indications other than those listed in the 'Coverage' section above.
- 4. Cosmetic sclerotherapy: Treatment of asymptomatic veins, or to improve the appearance of a non-symptomatic leg.
- 5. Non-compressive sclerotherapy.
- 6. Cyanoacrylate adhesion (VenaSeal® Closure System) in conjunction with sclerotherapy.
- 7. Sclerotherapy used in conjunction with:
 - a. Other sclerotherapy protocols, including but not limited to the COMPASS (echosclerotherapy) protocol, for the treatment of valvular incompetence (or reflux) of the GSV or SSV, or
 - b. A balloon catheter (e.g., KAVS procedure).

The following conditions are considered **contraindications/exclusions**:

- 1. Known allergy to the sclerosant or any component of the formulation.
- 2. Procedure employs device or sclerosants that have not been FDA-approved for such use.
- 3. Acute venous thrombosis (superficial, deep).

Molina Clinical Policy

Sclerotherapy and Adhesive Ablation for Varicose Veins:

Policy No. 431

Last Approval: 4/10/2024

Next Review Due By: April 2025



4. Pregnancy or lactation (if the indication is urgent, interrupt lactation for 2–3 days).
5. Local infection in the region of the sclerotherapy or severe generalized infection.
6. Advanced peripheral arterial disease.
7. Advanced collagen vascular disease.
8. High risk of thromboembolism (e.g., known history of thromboembolic events, known severe thrombophilia, active cancer).
9. Poor general state of health.
10. Long-term immobility or bed-ridden patient.
11. For foam sclerotherapy: A history of migraine headache and patent foramen ovale (relative contraindications to foam sclerotherapy due to a risk for microembolism).

QUANTITY LIMITATIONS

For eligible members who meet **ALL** the clinical requirements above for the relevant condition, the following quantity of treatments may be authorized:

1. Up to THREE (3) sclerotherapy treatment *sessions **per leg** may be authorized within one year.**
** A session is defined as one date of service in which sclerotherapy is performed. Minimum of six weeks between sessions.*
*** Year is defined as a rolling 12 months or 365 days from the time of initial authorization).*

Only ONE sclerotherapy service per treatment session should be reported for either leg, regardless of how many veins are treated per session.

2. Additional sclerotherapy sessions beyond the initial THREE sessions per leg within a year require submission of updated clinical information (post-treatment) for review.
3. Sclerotherapy should not be performed sooner than THREE (3) months following ablation, ligation, and stripping, or phlebectomy since the removal of the larger vessels may cause the smaller veins to shrink dramatically.
4. Recommended dosage does not exceed recommended dose in labeling or prescribing information:
 - Varithena: 5 mL per injection; 15 mL per session according to the prescribing information.
 - Sotradecol: 10 mL of 3% solution as a single treatment according to the prescribing information.

ADMINISTRATION

1. Sclerotherapy for the treatment of varicose veins is an **outpatient procedure**, usually in a physician office setting. Hospitalization is not required.
2. For administration of PEM 1%: Physicians must have experience with venous procedures and PEM 1% administration training (FDA Labeling).

DOCUMENTATION REQUIREMENTS. Molina Healthcare reserves the right to require that additional documentation be made available as part of its coverage determination; quality improvement; and fraud; waste and abuse prevention processes. Documentation required may include, but is not limited to, patient records, test results and credentials of the provider ordering or performing a drug or service. Molina Healthcare may deny reimbursement or take additional appropriate action if the documentation provided does not support the initial determination that the drugs or services were medically necessary, not investigational, or experimental, and otherwise within the scope of benefits afforded to the member, and/or the documentation demonstrates a pattern of billing or other practice that is inappropriate or excessive.

SUMMARY OF MEDICAL EVIDENCE

Number of Treatments/Retreatments

There is no consensus in the published scientific literature regarding the appropriate number of sclerotherapy treatments required to diminish varicose vein symptoms, and the number of treatments required to alleviate symptoms varies from individual patients.

Repeat treatment following initial varicose vein therapy is relatively common, however it is generally recommended to allow healing and the initial therapy's full benefits to be realized before undergoing additional treatment. At least 6 weeks passed prior to determining the success or failure of interventions in most clinical trials. Therefore, 6 weeks is

Molina Clinical Policy

Sclerotherapy and Adhesive Ablation for Varicose Veins:

Policy No. 431

Last Approval: 4/10/2024
Next Review Due By: April 2025



deemed an appropriate and conservative amount of time to reevaluate the need for further treatment in an effectively sclerosed vein; at that point, continued demonstration of significant disability and discomfort must be established prior to initiating further interventions (Weiss et al. 2014; Scovell 2024).

Choice of Sclerosing Agent

There is no high-quality evidence to support the use of one sclerosant over another in the short-term success of injectable sclerotherapy, according to systematic reviews of randomized trials of sclerotherapy for telangiectasias, reticular veins, or small, nonaxial varicose veins (Nakano et al. 2021; Tisi et al. 2006; Schwartz et al. 2011). Agents are selected based on availability and clinician experience. There are, however, some agent-specific advantages and distinctions in adverse effects (Nakano et al. 2021).

Sclerotherapy in Conjunction with other Procedures

KAVS procedure (catheter-assisted vein sclerotherapy) uses an intravascular catheter with a balloon at the distal end to temporarily block blood flow to the vein segment being treated, also referred to as endovenous catheter directed chemical ablation with balloon isolation. The peer-reviewed literature lacks evidence evaluating the safety and efficacy of endovenous catheter-directed chemical ablation in conjunction with balloon isolation as a therapy for varicose veins. The evidence is insufficient to conclude that this technology improves overall health, and it is not currently a widely accepted treatment for varicose veins.

The **Comprehensive Objective Mapping, Precise Image-guided Injection (echosclerotherapy), Antireflux Positioning, and Sequential Sclerotherapy (COMPASS)** is an UGS variation that has been proposed as a varicose vein treatment. Therapy employs UGS, which is then followed by a series of diagnostic ultrasound imaging procedures and sclerotherapy treatments to treat subsequent varicose veins and may require weeks or potentially months of treatment. Sclerotherapy / echosclerotherapy of the underlying refluxing great or small saphenous veins is associated with a higher rate of recurrence when compared to ligation and stripping, according to controlled studies (Belcaro et al. 2003). There are notable flaws in the study published by Belcaro et al. including a lack of specific information regarding participant selection criteria, no description of the randomization process, and a lack of appropriate comparison groups, such as standard surgical treatment consisting of vein stripping and ligation. Additionally, one of the surgical reference arms was a retrospective historical control group that was not randomly assigned. Furthermore, rather than a randomization arm, one of the surgical reference arms was a retrospective historical control group. Moreover, in the COMPASS protocol, retreatment because of continued ultrasound monitoring was considered as a continuation of the previous therapy, as opposed to actual recurrences or treatment failures. This aspect of the COMPASS protocol may be responsible for the low "recurrence rate" reported in the published studies. Individuals are considered in the latter "phases" of therapy for extended periods of time under the COMPASS protocol. According to some reports, individuals have received therapy for more than a year. In comparison, alternative treatment methods such as standard surgical techniques, laser ablation, or RFA procedures are completed in 7 to 10 days.

Cyanoacrylate adhesion (also referred to as cyanoacrylate superglue, n-butyl-cyanoacrylate) (e.g., VenaSeal Closure System), a medical-grade adhesive, is a transparent, freely flowing liquid that solidifies upon contact with body fluids or tissue and polymerizes in the vessel via an anionic mechanism. In conjunction with ultrasound and manual compression, the adhesive is injected gradually along the length of the target vein below the knee to seal it off and redirect blood flow to less tortuous veins. The minimally invasive office procedure usually takes less than half an hour on average. The VenaSeal Closure System was approved by the FDA through the PMA process in 2015 for the permanent closure of clinically significant venous reflux through endovascular embolization with coaptation (FDA 2015). However, the evidence evaluated is insufficient to determine that the technology results in an improvement in the net health outcome (Kolluri et al. 2020; Morrison et al. 2020).

Kolluri et al. (2020) conducted a network meta-analysis of RCTs to compare the 6-month outcomes of 20 heterogeneous RCTs evaluating cyanoacrylate adhesion, endovenous laser ablation, RFA, mechanochemical ablation, sclerotherapy, and surgery for the treatment of chronic venous insufficiency. Among these 20 RCTs, only 3 RCTs assessed cyanoacrylate adhesion, however only in comparison to RFA (Morrison et al. 2015; Morrison et al. 2017; Gibson et al. 2018). This analysis does not provide conclusive evidence of the effect of cyanoacrylate adhesion in comparison to the other included treatments.

Molina Clinical Policy

Sclerotherapy and Adhesive Ablation for Varicose Veins:

Policy No. 431

Last Approval: 4/10/2024
Next Review Due By: April 2025



Morrison et al. (2020) published results from a 5-year extension study of VeClose trial. The primary outcome was complete closure of the target vein. The 60-month visit was completed by 89 of the initial 222 individuals, including 47 from the VenaSeal group, 33 from the RFA group, and 9 additional nonrandomized VenaSeal recipients. No further recanalization episodes occurred in either group between 36 and 60 months of follow-up. At the conclusion of the study, the freedom from recanalization rates in the randomized VenaSeal and RFA groups were 91.4% and 85.2%, respectively, and both groups indicated sustained increases in quality-of-life scores. Additionally, 39.4% of the RFA group and 41.1% of the VenaSeal group had CEAP clinical classes at least two lower than they had at baseline. Between the 36- and 60-month follow-ups, neither group experienced any long-term device or procedure-related major adverse events. The results of this research are compelling yet limited, only 40% of the initial study participants continuing and relatively few participants within each group for analysis.

A Health Technology Assessment (HTA), Cyanoacrylate Embolization with the VenaSeal Closure System (Medtronic Inc.) for the Treatment of Varicose Veins, evaluated the safety and efficacy of cyanoacrylate embolization (CAE) with the VenaSeal closure system (Medtronic Inc.) for the treatment of symptomatic varicose veins. This HTA also evaluates the efficacy and safety of the VenaSeal closure system in comparison to other endovenous treatments and surgical vein extraction. A low-quality body of evidence indicates that the use of the VenaSeal closure system for cyanoacrylate embolization (CAE) of varicose veins in adults is associated with a high rate of successful venous closure that lasts at least one year. The report notes that the efficacy and safety of CAE may be comparable to that of RFA, endovenous laser ablation, and mechanochemical ablation, and CAE may be associated with significantly fewer and less severe adverse events than vein stripping. However, due to the limitations of individual studies, the small number of studies reporting the same patient-centered outcomes, the limited evidence of comparative efficacy for the majority of clinical alternatives, and the limited follow-up beyond one year, the HTA noted that substantial uncertainty still exists for this approach (Hayes 2023).

Systematic Reviews

de Ávila Oliveira et al. (2021) conducted a systematic review assessing the effectiveness and safety of injection sclerotherapy for the treatment of varicose veins in 28 studies involving 4278 participants. The authors concluded that there was limited or no evidence comparing one foam concentration to another, foam to liquid sclerotherapy, foam to any other substance, or one procedure to another. To increase the certainty of the evidence, high-quality trials utilizing standardized sclerosant doses, with clearly defined core outcome sets and measurement time points, are required.

Whing et al. (2021), in a systematic review, compared interventions for GSV incompetence. The review included 24 RCTs (N = 5135) and the duration of follow-up for included trials ranged from 5 weeks to 8 years. Based on pooled data from 4 relevant RCTs (n = 954), ultrasound-guided foam sclerotherapy was inferior to ligation and stripping for technical success up to 5 years (low-certainty evidence), and beyond 5 years based on 3 RCTs (n=525) (moderate-certainty evidence). There was no significant difference between treatments for recurrence up to 3 years based on 3 RCTs (n=822) and beyond 5 years based on 3 RCTs (n = 639). Similarly, technical success was improved with endovenous laser ablation over ultrasound-guided foam sclerotherapy up to 5 years based on data from 3 RCTs (n = 588) (low-certainty evidence), and beyond 5 years based on data from 3 RCTs (n = 534) (low-certainty evidence). There was no significant difference between endovenous laser ablation and ultrasound-guided foam sclerotherapy for recurrence up to 3 years based on data from 2 RCTs (n = 443), and at 5 years based on data from 2 RCTs (n = 418).

Tisi et al. (2006) conducted a systematic review that compared sclerotherapy and graduated compression stockings or observation. RCTs of injection sclerotherapy versus graduated compression stockings or 'observation', or comparing different sclerosants, doses, formulations, and post-compression bandaging techniques on individuals with symptomatic and/or cosmetic varicose veins or thread veins were considered for inclusion in the review. Complication and recurrence rates were reviewed, as were improvements in symptoms and cosmetic appearance. Sclerotherapy was effective in reducing symptoms and appearance of varicose veins. Evidence from RCTs suggests that the choice of sclerosant, dose, formulation (foam versus liquid), local pressure dressing, degree and length of compression have no significant effect on the efficacy of sclerotherapy for varicose veins. The evidence supports the current place of sclerotherapy in modern clinical practice, which is usually limited to treatment of recurrent varicose veins following surgery and thread veins.

Meta-Analysis

Molina Clinical Policy

Sclerotherapy and Adhesive Ablation for Varicose Veins:

Policy No. 431

Last Approval: 4/10/2024
Next Review Due By: April 2025



Hamann et al. (2017) performed a meta-analysis of 5-year follow-up in 3 RCTs and 10 follow-up studies. The meta-analysis included 611 legs treated with endovenous laser ablation, 549 legs treated with high ligation and stripping, 121 legs treated with sclerotherapy, and 114 legs treated with both high ligation and endovenous laser ablation. Compared to the other three treatments, ultrasound-guided sclerotherapy had significantly worse outcomes, with anatomic success rates of 34% versus 83% to 88% for the other three treatments.

Brittenden et al. (2019) published a randomized, 5-year comparative efficacy study evaluating quality of life outcomes among patients with primary varicosities who underwent endovenous laser ablation (n=210), sclerotherapy (n=286), or surgery (n=289) of the GSV or SSV. At year 5, 595 (75%) of the 798 trial participants completed the quality-of-life surveys (a sample size analysis accounted for 30% loss to follow-up). The Aberdeen Varicose Vein Questionnaire (AAVQ) scores of patients who underwent laser ablation or surgery were considerably higher than those who received foam sclerotherapy. Further treatment was received by 11% of the laser ablation group, 14% of the foam sclerotherapy group, and 7% of the surgery group.

PEM 1% (Varithena) was approved under a new drug application for the treatment of varicose veins in 2013. Efficacy data were derived from two randomized, blinded, multicenter studies. One compared polidocanol at 0.5%, 1.0%, and 2.0% with endovenous placebo or a subtherapeutic dose of polidocanol foam. The primary endpoint was an improvement in symptoms at week 8, as measured by the Varicose Vein Symptoms Questionnaire. The improvement in symptoms was greater in the pooled polidocanol treatment group and in each of the individual dose-concentration groups compared with vehicle alone. Secondary and tertiary endpoints (appearance, duplex ultrasound response, and quality of life) were also significantly better in the polidocanol groups than in the control groups.

Todd et al. (2014) published the second study, VANISH-2, a multicenter pivotal trial that was randomized, blinded, and assessed the safety and effectiveness of PEM. Participants were randomly assigned to receive PEM at 0.5%, 1.0%, or a placebo. PEM 0.5% and 1.0% were reported as superior to placebo in 232 treated participants (n = 232), with a larger improvement in symptoms and greater improvements in assessments of appearance. The findings were supported by duplex ultrasound and other clinical measurements. Compared to 39% of the placebo group, 60% of the subjects who received PEM experienced a negative reaction. The study concluded that PEM provided clinically meaningful benefit in treating varicose vein symptoms and appearance in patients. PEM was a safe and effective minimally invasive treatment for patients with a wide range of vein disease (CEAP clinical class C2 to C6) and GSV diameters ranging from 3.1 to 19.4 mm. Endovenous polidocanol microfoam treatment was associated with mild to moderately manageable side effects. There was no increase in neurologic adverse events after treatment with polidocanol injectable foam, and no adverse cardiac or cardiopulmonary effects were observed. Occlusion rates with Varithena are comparable to those reported for endovenous laser ablation or stripping. Data from both studies revealed a dose-response range of 0.5% to 2.0% for improvement in appearance and 0.5% to 1.0% for Duplex responders. The FDA approved the polidocanol 1.0% dose.

King et al. (2015) confirmed VANISH-2 results in a multi-center parallel study of 284 subjects. Treatment with PEM 1% and PEM 2% resulted in similar side effects, was equally effective in improving symptoms and appearance, and had a similar duplex response rate, according to the authors.

Vasquez et al. (2017) published the results of a randomized, placebo-controlled, blinded study that evaluated the efficacy and safety of PEM (0.5% and 1.0%) and placebo each administered with endovenous thermal ablation. Endovenous thermal ablation (ETA) plus placebo (n = 38), polidocanol 0.5% (n = 39), or 1% (n = 40) was administered to a total of 117 patients who were candidates for both ETA and treatment of visible varicosities. PEM significantly improved physician-rated vein appearance at Week 8; patient-assessed appearance trended similarly. At 6-month follow-up, physician (70.9% vs. 42.1%) and patient (67.0% vs. 50.0%) ratings of the percentage of patients who achieved a clinically meaningful change were significantly higher with (pooled) PEM than with placebo. The proportion of patients who required additional treatment for residual varicosities between week 8 and month 6 was reduced by a small amount (13.9% for polidocanol versus 23.0% for placebo). Combination treatment with ETA and PEM was generally well-tolerated. The AEs observed were those typical of the treatments administered. The authors concluded that adding PEM to ETA improved physician-assessed appearance scores and reduced the proportion of patients with residual SFJ reflux and those who received additional treatment. Furthermore, there was a consistent trend across the other study endpoints indicating improved efficacy with the addition of PEM to ETA therapy when compared to placebo and ETA.

A health technology assessment (HTA) addressing the use of PEM 1% for treating varicose veins (incompetent great

Molina Clinical Policy

Sclerotherapy and Adhesive Ablation for Varicose Veins:

Policy No. 431

Last Approval: 4/10/2024
Next Review Due By: April 2025



saphenous veins, accessory saphenous veins, and visible varicosities above and below the knee) in adults as potential but unproven benefit (Hayes 2022). The HTA noted the low-quality evidence suggesting that PEM 1% may provide symptomatic relief and result in the occlusion and elimination of reflux. Significant uncertainty exists regarding the comparative effectiveness of PEM 1% in comparison to other sclerosants as well as other surgical techniques. Well-designed, independent RCTs are also recommended to further demonstrate the comparative safety and efficacy of PEM 1%, assess the duration of its therapeutic effects, and define the appropriate patient selection criteria for its administration.

National and Specialty Organizations

The **American Vein and Lymphatic Society (AVL, previously named the American College of Phlebology [ACP])** published guidelines (2017) following a systematic review of the literature on the clinical impact and treatment of incompetent accessory saphenous veins. The ACP developed a consensus opinion using an accepted process for guideline development that patients with symptomatic incompetence of the accessory great saphenous veins (anterior and posterior accessory saphenous veins) be treated with endovenous thermal ablation (laser or radiofrequency) or ultrasound-guided foam sclerotherapy to reduce symptomatology.

The published guidelines on the treatment of superficial vein disease in 2015:

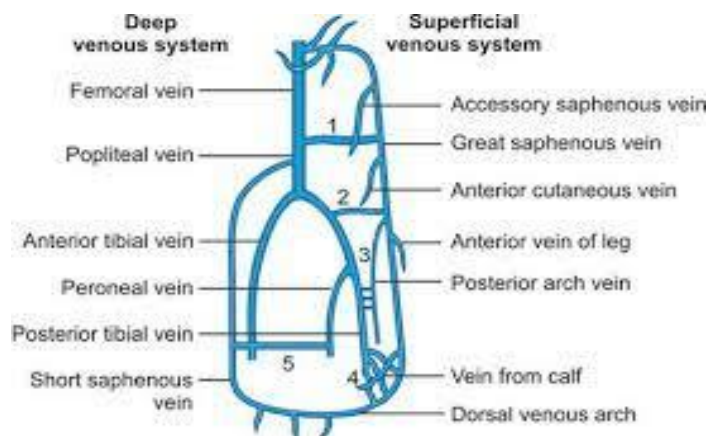
- AVL issued a Grade 1 recommendation based on high-quality evidence that compression is an effective method for symptom management, but when patients have a correctable source of reflux, definitive treatment should be offered unless contraindicated. When a definitive treatment is available, AVL advises against the use of compression therapy.
- Endovenous thermal ablation is the preferred treatment for saphenous and accessory saphenous vein incompetence (a strong recommendation) and mechanochemical ablation may also be used to treat venous reflux (a weak recommendation), according to moderate quality evidence.

Ultrasound-Guided Sclerotherapy

The **American Vein and Lymphatic Society (formerly American College of Phlebology)** (2016) recommend that non-clinically visible symptomatic tributary veins be treated using ultrasound-guided liquid sclerotherapy or foam chemical ablation.

The **European Society of Vascular Surgery** (2022) Clinical Practice Guidelines specifically notes 'For patients with chronic venous disease requiring treatment of varicose tributaries, ambulatory phlebectomy, ultrasound guided foam sclerotherapy or a combination of both are recommended'.

SUPPLEMENTAL INFORMATION



Reference: Rajamahendran R. Long Cases in General Surgery 2nd edition. Chapter 8: Varicose Veins. Available from [Jaypee Brothers Medical Publishers \(P\) Ltd.](#)

Molina Clinical Policy
Sclerotherapy and Adhesive Ablation for Varicose Veins:
Policy No. 431

Last Approval: 4/10/2024
 Next Review Due By: April 2025



Saphenous Veins

- Accessory saphenous veins: a vein running in the thigh parallel to the great and small saphenous veins.
- GSV (also referred to as long or large saphenous vein): the longest vein in the body, extending from the dorsum of the foot to just below the inguinal ligament, where it opens into the femoral vein.
- SSV (also referred to as the short or lesser saphenous vein): the vein that continues the marginal vein from behind the malleolus and passes up the back of the leg to the knee joint, where it opens into the popliteal vein. Also known as the short or lesser saphenous vein.

Superficial Veins: Veins that run in the subcutaneous tissue in the lower limbs; the GSV and the SSV are the two major superficial veins.

Reticular Vein: Dilated bluish subdermal vein, generally 1 mm to less than 3 mm in diameter and usually tortuous.

Telangiectasia: a type of varicose veins also known as spider veins; small bluish-purple veins, usually found in clusters on the leg.

Tributary Vein: A superficial vein branch that flows into larger veins.

Varicose Vein or Varicosity: Veins that are abnormally swollen or enlarged due to venous wall weakness. Measured in an upright position these veins are 3 mm in diameter or greater.

Clinical, Etiological, Anatomical, Pathophysiological (CEAP) Classification (Lurie et al., 2020)

Classification for chronic venous disorders is based on clinical severity (C), etiology (E), anatomy (A), and pathophysiology (P) to improve the accuracy of the diagnosis (CEAP):

Clinical classification	
C0	No visible or palpable signs of disease
C1	Telangiectasias or reticular veins
C2	Varicose veins
C3	Edema
C4a	Pigmentation or eczema
C4b	Lipodermatosclerosis or atrophic blanche
C5	Healed venous ulcer
C6	Active venous ulcer
S	Symptomatic, including ache, pain, tightness, skin irritation, heaviness, muscle cramps, and other complaints attributable to venous dysfunction
A	Asymptomatic
Etiologic classification	
Ec	Congenital
Ep	Primary
Es	Secondary (post-thrombotic)
En	No venous cause identified
Anatomic classification	
As	Superficial veins
Ap	Perforator veins
Ad	Deep veins
An	No venous location identified
Pathophysiologic	
Pr	Reflux
Po	Obstruction
Pr, o	Reflux and obstruction
Pn	No venous pathophysiology identifiable

Venous Clinical Severity Score (VCSS) is an assessment tool used to complement the CEAP scoring system of varicose veins. This tool uses both physician-determined, and patient-reported elements, which include ten parameters graded from zero to three depending on severity (pain, varicose veins, venous edema, pigmentation, inflammation, induration, number of active ulcers, duration of active ulcers, size of active ulcers, and compliance with compression therapy) to establish a baseline against which to compare progression over time and/or effects of intervention (UpToDate, 2023).

Pain or Other Discomfort (i.e., aching, heaviness, fatigue, soreness, burning)
 None = 0: None

Molina Clinical Policy
Sclerotherapy and Adhesive Ablation for Varicose Veins:
Policy No. 431



Last Approval: 4/10/2024
 Next Review Due By: April 2025

Mild = 1: Occasional pain or discomfort that does not restrict daily activities
 Moderate = 2: Daily pain or discomfort that interferes with, but does not prevent, regular daily activities
 Severe = 3: Daily pain or discomfort that limits most regular daily activities

Varicose Veins

None = 0: None

Mild = 1: Few, scattered, varicosities that are confined to branch veins or clusters. Includes “corona phlebectatica” (ankle flare), defined as greater than 5 blue telangiectasia at the inner or sometimes the outer edge of the foot

Moderate = 2: Multiple varicosities that are confined to the calf or the thigh

Severe = 3: Multiple varicosities that involve both the calf and the thigh

Venous Edema

None= 0: None

Mild= 1: Edema that is limited to the foot and ankle

Moderate= 2: Edema that extends above the ankle but below the knee

Severe= 3: Edema that extends to the knee or above

Skin Pigmentation

None = 0: None, or focal pigmentation that is confined to the skin over varicose veins

Mild = 1: Pigmentation that is limited to the perimalleolar area

Moderate = 2: Diffuse pigmentation that involves the lower third of the calf

Severe = 3: Diffuse pigmentation that involves more than the lower third of the calf

Induration

None = 0: None

Mild = 1: Induration that is limited to the peri-malleolar area

Moderate = 2: Induration that involves the lower third of the calf

Severe = 3: Induration that involves more than the lower third of the calf

Active Ulcer Number

None = 0: None

Mild = 1: One Ulcer

Moderate = 2: Two Ulcers

Severe = 3: Three Ulcers

Active Ulcer

None = 0: No active ulcers

Mild = 1: Ulceration present for less than 3 mo

Moderate = 2: Ulceration present for 3-12 mo

Severe = 3: Ulceration present for greater than 12 mo

Active Ulcer Size

None = 0: No active ulcer

Mild = 1: Ulcer less than 2 cm in diameter

Moderate = 2: Ulcer 2-6 cm in diameter

Severe = 3: Ulcer greater than 6 cm in diameter

Use of Compression Therapy (based on compliance)

None = 0: Not used

Mild = 1: Intermittent use

Moderate = 2: Wears stockings most days

Severe = 3: Full compliance: stockings

CODING & BILLING INFORMATION

CPT (Current Procedural Terminology) Codes

Code	Description
36465	Injection of non-compounded foam sclerosant with ultrasound compression maneuvers to guide dispersion of the injectate, inclusive of all imaging guidance and monitoring; single incompetent extremity truncal vein (e.g., great saphenous vein, accessory saphenous vein)
36466	Injection of non-compounded foam sclerosant with ultrasound compression maneuvers to guide dispersion of the injectate, inclusive of all imaging guidance and monitoring; multiple incompetent truncal veins (e.g., great saphenous vein, accessory saphenous vein), same leg
36468	Injection(s) of sclerosant for spider veins (telangiectasia), limb or trunk

Molina Clinical Policy

Sclerotherapy and Adhesive Ablation for Varicose Veins:

Policy No. 431



Last Approval: 4/10/2024
Next Review Due By: April 2025

36470	Injection of sclerosant; single incompetent vein (other than telangiectasia)
36471	Injection of sclerosant; multiple incompetent veins (other than telangiectasia), same leg
36482	Endovenous ablation therapy of incompetent vein, extremity, by transcatheter delivery of a chemical adhesive (e.g., cyanoacrylate) remote from the access site, inclusive of all imaging guidance and monitoring, percutaneous; first vein treated
36483	Endovenous ablation therapy of incompetent vein, extremity, by transcatheter delivery of a chemical adhesive (e.g., cyanoacrylate) remote from the access site, inclusive of all imaging guidance and monitoring, percutaneous; subsequent vein(s) treated in a single extremity, each through separate access sites (List separately in addition to code for primary procedure)

CODING DISCLAIMER. Codes listed in this policy are for reference purposes only and may not be all-inclusive. Deleted codes and codes which are not effective at the time the service is rendered may not be eligible for reimbursement. Listing of a service or device code in this policy does not guarantee coverage. Coverage is determined by the benefit document. Molina adheres to Current Procedural Terminology (CPT®), a registered trademark of the American Medical Association (AMA). All CPT codes and descriptions are copyrighted by the AMA; this information is included for informational purposes only. Providers and facilities are expected to utilize industry standard coding practices for all submissions. When improper billing and coding is not followed, Molina has the right to reject/deny the claim and recover claim payment(s). Due to changing industry practices, Molina reserves the right to revise this policy as needed.

APPROVAL HISTORY

04/10/2024	Policy reviewed, no changes to coverage criteria. Summary of Medical Evidence and References updated.
10/12/2023	Removed reference to "Continuation to Treatment" criteria.
04/20/2023	New policy. IRO Peer Review completed on 3/17/2023 by a practicing physician board-certified in Vascular Surgery.

REFERENCES

- American Vein and Lymphatic Society (AVLS) (formerly American College of Phlebology). Practice guidelines: Superficial venous disease rev020316. Accessed February 2023.
- Antani MR, Dattilo JB. Varicose Veins. In: StatPearls [Internet]. Treasure Island (FL). Updated August 8, 2023. Accessed February 27, 2023. <https://www.ncbi.nlm.nih.gov/books/NBK470194/>
- Asclera (polidocanol) [prescribing information]. Coral Springs, FL: Methapharm Inc; February 2022.
- Belcaro G, Cesarone MR, Di Renzo A, et al. Foam-sclerotherapy, surgery, sclerotherapy, and combined treatment for varicose veins: a 10-year, prospective, randomized, controlled, trial (VEDICO trial). *Angiology*. 2003 May-Jun;54(3):307-15. doi: 10.1177/000331970305400306. PMID: 12785023.
- Brittenden J, Cooper D, Dimitrova M, et al. Five-year outcomes of a randomized trial of treatments for varicose veins. *N Engl J Med*. 2019 Sep 5;381(10):912-922. doi: 10.1056/NEJMoa1805186. PMID: 31483962.
- Centers for Medicare and Medicaid Services (CMS). Medicare coverage database: Local coverage determination – treatment of chronic venous insufficiency of the lower extremities (L38720). Effective December 27, 2020. Accessed February 26, 2024. <https://www.cms.gov/medicare-coverage-database/search.aspx>
- Centers for Medicare and Medicaid Services (CMS). Medicare coverage database – (Search: varicose veins, sclerotherapy, Varithena or polidocanol). Accessed February 28, 2024. <https://www.cms.gov/medicare-coverage-database/search.aspx>.
- de Ávila Oliveira R, Riera R, Vasconcelos V, et al. Injection sclerotherapy for varicose veins. *Cochrane Database Syst Rev*. 2021 Dec 10;12(12):CD001732. doi: 10.1002/14651858.CD001732.pub3. PMID: 34883526; PMCID: PMC8660237.
- De Maeseneer MG, Kakkos SK, Aherne T, et al. ME. Editor's Choice - European Society for Vascular Surgery (ESVS) 2022 Clinical practice guidelines on the management of chronic venous disease of the lower limbs. *Eur J Vasc Endovasc Surg*. 2022 Feb;63(2):184-267. doi: 10.1016/j.ejvs.2021.12.024. Epub 2022 Jan 11. Erratum in: *Eur J Vasc Endovasc Surg*. 2022 Aug-Sep;64(2-3):284-285. PMID: 35027279.
- Evolent cardio policy: Lower extremity venous sclerotherapy. Policy number UM CARDIO_1254. Effective date January 26, 2024.
- Gibson K, Kabnick L; Varithena® 013 Investigator Group. A multicenter, randomized, placebo-controlled study to evaluate the efficacy and safety of Varithena® (polidocanol endovenous microfoam 1%) for symptomatic, visible varicose veins with saphenofemoral junction incompetence. *Phlebology*. 2017 Apr;32(3):185-193. doi: 10.1177/0268355516635386. Epub 2016 Jul 9. PMID: 27013511; PMCID: PMC5405826.
- Hamann SAS, Giang J, De Maeseneer MGR, et al. Editor's Choice - Five year results of great saphenous vein treatment: A Meta-analysis. *Eur J Vasc Endovasc Surg*. 2017 Dec;54(6):760-770. doi: 10.1016/j.ejvs.2017.08.034. Epub 2017 Oct 14. PMID: 29033337.
- Hayes. Cyanoacrylate embolization with the VenaSeal Closure System (Medtronic Inc.) for the treatment of varicose veins. Published September 2, 2022. Updated September 1, 2023. Accessed February 29, 2024. <https://evidence.hayesinc.com/>.
- Hayes. Polidocanol endovenous microfoam (Varithena) 1% for treatment of varicose veins. Published September 16, 2019. Updated November 10, 2022. Accessed February 29, 2024. <https://evidence.hayesinc.com/>.
- King JT, O'Byrne M, Vasquez M, et al. Treatment of truncal incompetence and varicose veins with a single administration of a new polidocanol endovenous microfoam preparation improves symptoms and appearance. *Eur J Vasc Endovasc Surg*. 2015 Dec;50(6):784-93. doi: 10.1016/j.ejvs.2015.06.111. Epub 2015 Sep 16. PMID: 26384639.
- Kolluri R, Chung J, Kim S, et al. Network meta-analysis to compare VenaSeal with other superficial venous therapies for chronic venous insufficiency. *J Vasc Surg Venous Lymphat Disord*. 2020 May;8(3):472-481.e3. doi: 10.1016/j.jvsv.2019.12.061. Epub 2020 Feb 14. PMID: 32063522.

Molina Clinical Policy

Sclerotherapy and Adhesive Ablation for Varicose Veins:

Policy No. 431

Last Approval: 4/10/2024

Next Review Due By: April 2025



17. Lurie F, Passman M, Meisner M, et al. The 2020 update of the CEAP classification system and reporting standards. *J Vasc Surg Venous Lymphat Disord.* 2020 May;8(3):342-352. doi: 10.1016/j.jvsv.2019.12.075. Epub 2020 Feb 27. Erratum in: *J Vasc Surg Venous Lymphat Disord.* 2021 Jan;9(1):288. PMID: 32113854.
18. Mathes B. Diagnostic evaluation of lower extremity chronic venous disease. Updated November 13, 2023. Accessed February 27, 2024. <http://www.uptodate.com>
19. Morrison N, Gibson K, Vasquez M, et al. Five-year extension study of patients from a randomized clinical trial (VeClose) comparing cyanoacrylate closure versus radiofrequency ablation for the treatment of incompetent great saphenous veins. *J Vasc Surg Venous Lymphat Disord.* 2020 Nov;8(6):978-989. doi: 10.1016/j.jvsv.2019.12.080. Epub 2020 Mar 20. PMID: 32205125.
20. Morrison N, Gibson K, McEnroe S, et al. Randomized trial comparing cyanoacrylate embolization and radiofrequency ablation for incompetent great saphenous veins (VeClose). *J Vasc Surg.* 2015 Apr;61(4):985-94. doi: 10.1016/j.jvs.2014.11.071. Epub 2015 Jan 31. PMID: 25650040
21. Morrison N, Gibson K, Vasquez M, et al. VeClose trial 12-month outcomes of cyanoacrylate closure versus radiofrequency ablation for incompetent great saphenous veins. *J Vasc Surg Venous Lymphat Disord.* 2017 May;5(3):321-330. doi: 10.1016/j.jvsv.2016.12.005. Epub 2017 Mar 6. PMID: 28411697.
22. Nakano LC, Cacione DG, Baptista-Silva JC, et al. Treatment for telangiectasias and reticular veins. *Cochrane Database Syst Rev.* 2021 Oct 12;10(10):CD012723. doi: 10.1002/14651858.CD012723.pub2. PMID: 34637138; PMCID: PMC8507602.
23. Raetz J, Wilson M, Collins K. Varicose Veins: Diagnosis and Treatment. *Am Fam Physician.* 2019 Jun 1;99(11):682-688. PMID: 31150188.
24. Schwartz L, Maxwell H. Sclerotherapy for lower limb telangiectasias. *Cochrane Database Syst Rev.* 2011 Dec 7;2011(12):CD008826. doi: 10.1002/14651858.CD008826.pub2. PMID: 22161437; PMCID: PMC7389636.
25. Scovell S. Injection sclerotherapy techniques for the treatment of telangiectasias, reticular veins, and small varicose veins. Updated January 3, 2024. Accessed February 27, 2024. <http://www.uptodate.com>
26. Sotradecol (sodium tetradecyl sulfate) [prescribing information]. Morgantown, WV: Mylan Institutional LLC; August 2021.
27. Swoboda SJ, Schumann H, Kiritsi D. A leg ulcer with pulsating varicose veins - from the legs to the heart. *Int Wound J.* 2018 Feb;15(1):62-64. doi: 10.1111/iwj.12834. Epub 2017 Nov 7. PMID: 29115044; PMCID: PMC7949940.
28. Tisi PV, Beverley C, Rees A. Injection sclerotherapy for varicose veins. *Cochrane Database Syst Rev.* 2006 Oct 18;(4):CD001732. doi: 10.1002/14651858.CD001732.pub2. Update in: *Cochrane Database Syst Rev.* 2021 Dec 10;12:CD001732.
29. Todd KL 3rd, Wright DI; VANISH-2 Investigator Group. The VANISH-2 study: A randomized, blinded, multicenter study to evaluate the efficacy and safety of polidocanol endovenous microfoam 0.5% and 1.0% compared with placebo for the treatment of saphenofemoral junction incompetence. *Phlebology.* 2014 Oct;29(9):608-18. doi: 10.1177/0268355513497709. Epub 2013 Jul 17. PMID: 23864535.
30. United States Food and Drug Administration (FDA). KAVS Catheter. Premarket Notification 510(k). 510(k) No. K052844. Rockville, MD. Available from FDA. Published March 20, 2006. Accessed February 29, 2024.
31. United States Food and Drug Administration (FDA) Center for Drug Evaluation and Research. Summary review: 205098 Varithena. 2013; https://www.accessdata.fda.gov/drugsatfda_docs/nda/2013/205098Orig1s000SumR.pdf.
32. United States Food and Drug Administration (FDA) Center for Drug Evaluation and Research. Summary review: 021201 Asclera. 2010; https://www.accessdata.fda.gov/drugsatfda_docs/nda/2010/021201s000_Sumr.pdf.
33. United States Food and Drug Administration (FDA). Venaseal closure system. PMA P140018. Rockville, MD. Available from FDA. Published February 20, 2015. Accessed February 29, 2024.
34. Varithena (polidocanol) [prescribing information]. West Conshohocken, PA: Biocompatibles Inc; November 2021.
35. Vasquez M, Gasparis AP; Varithena® 017 Investigator Group. A multicenter, randomized, placebo-controlled trial of endovenous thermal ablation with or without polidocanol endovenous microfoam treatment in patients with great saphenous vein incompetence and visible varicosities. *Phlebology.* 2017 May;32(4):272-281. doi: 10.1177/0268355516637300. Epub 2016 Mar 7. PMID: 26957489; PMCID: PMC5405840.
36. Weiss MA, Hsu JT, Neuhaus I, et al. Consensus for sclerotherapy. *Dermatol Surg.* 2014 Dec;40(12):1309-18. doi: 10.1097/DSS.0000000000000225. PMID: 25418805.
37. Whing J, Nandhra S, Nesbitt C, et al. Interventions for great saphenous vein incompetence. *Cochrane Database Syst Rev.* 2021 Aug 11;8(8):CD005624. doi: 10.1002/14651858.CD005624.pub4. PMID: 34378180; PMCID: PMC8407488.