

Molina Clinical Policy

Sclerotherapy and Adhesive Therapy for Varicose Veins

Policy No. 431

Last Approval: 04/08/2026

Next Review Due By: April 2027



DISCLAIMER

This Molina Clinical Policy (MCP) is intended to facilitate the Utilization Management process. Policies are not a supplementation or recommendation for treatment; Providers are solely responsible for the diagnosis, treatment, and clinical recommendations for the Member. It expresses Molina's determination as to whether certain services or supplies are medically necessary, experimental, investigational, or cosmetic for purposes of determining appropriateness of payment. The conclusion that a particular service or supply is medically necessary does not constitute a representation or warranty that this service or supply is covered (e.g., will be paid for by Molina) for a particular Member. The Member's benefit plan determines coverage – each benefit plan defines which services are covered, which are excluded, and which are subject to dollar caps or other limits. Members and their Providers will need to consult the Member's benefit plan to determine if there are any exclusion(s) or other benefit limitations applicable to this service or supply. If there is a discrepancy between this policy and a Member's plan of benefits, the benefits plan will govern. In addition, coverage may be mandated by applicable legal requirements of a State, the Federal government or CMS for Medicare and Medicaid Members. CMS's Coverage Database can be found on the CMS website. The coverage directive(s) and criteria from an existing National Coverage Determination (NCD) or Local Coverage Determination (LCD) will supersede the contents of this MCP and provide the directive for all Medicare members. References included were accurate at the time of policy approval and publication.

OVERVIEW

Varicose veins are a type of venous insufficiency characterized by enlarged, twisted, and dilated veins due to chronic valvular dysfunction. They primarily affect the main superficial veins of the lower extremities, including the great saphenous vein (GSV), the small saphenous vein (SSV), and their tributaries. Varicose veins are defined as subcutaneous veins with a diameter of at least 3 mm and are part of a spectrum of chronic venous disorders. These disorders range from fine telangiectasias, or spider veins (less than 1 mm), and reticular veins (1-3 mm) to chronic venous insufficiency. The primary cause of varicose veins is valvular insufficiency, leading to venous reflux, with only about 5-20% of cases occurring as a result of a secondary condition such as deep vein thrombosis, pelvic tumor, or arteriovenous fistulas (Beneat & Oropallo 2024; Gloviczki 2024).

Symptoms can vary, with some patients presenting as asymptomatic to localized discomfort at the affected vein site, which may be unilateral or bilateral. While many cases are primarily a cosmetic concern and do not require medical treatment, some individuals may experience pain, aching, heaviness, cramping, throbbing, restlessness, and swelling. Severe venous insufficiency can lead to complications such as infection, superficial thrombophlebitis, venous ulcers, subcutaneous tissue loss, lipodermatosclerosis, and, in rare cases, significant external hemorrhage due to varicose vein rupture (Raetz et al. 2019).

Diagnosis of venous insufficiency is typically based on clinical examination revealing varicosities measuring 3 mm or more. However, a physical exam alone may not fully assess the underlying physiological properties, making ultrasound and other non-invasive tests essential for a comprehensive evaluation (Mathes & Fukaya 2025). Duplex ultrasonography is the preferred imaging technique for diagnosing superficial venous incompetence and assessing venous disease in the lower limbs. It is commonly used preoperatively to map varicose veins, tributaries, and incompetent perforating veins. Current medical literature does not support the routine use of repeat Duplex or Doppler studies as part of sclerotherapy treatment. Furthermore, noninvasive imaging is not considered medically necessary unless venous symptoms or clinical signs of insufficiency or reflux are present. Visual documentation, such as photographs or diagrams, can assist in determining the extent and severity of varicosities. The CEAP (Clinical, Etiological, Anatomical, and Pathophysiological) classification system provides a standardized approach for categorizing chronic venous disorders based on clinical presentation, underlying cause, affected anatomy, and venous pathology (Lurie et al. 2020).

Treatment for symptomatic varicose veins typically begins with conservative approaches, including compression stockings and lifestyle modifications such as reducing prolonged standing, elevating the legs, and managing weight. Severe cases involving ulceration, thrombosis, or persistent discomfort may require surgical or minimally invasive treatments, including vein stripping, sclerotherapy, endovenous laser ablation, and radiofrequency ablation. Patients with venous ulcers and superficial venous insufficiency should undergo treatment of the superficial vein and wound healing before considering sclerotherapy. If symptoms persist after conservative treatment, and venous reflux of ≥ 500 milliseconds in the saphenous veins is confirmed via duplex ultrasound, interventional treatment is recommended, particularly for chronic venous disease classified as CEAP C2 or higher (De Maeseneer et al. 2022; AVLS 2016).

Molina Clinical Policy

Sclerotherapy and Adhesive Therapy for Varicose Veins

Policy No. 431

Last Approval: 04/08/2026

Next Review Due By: April 2027



Sclerotherapy, or endovenous chemical ablation, is a procedure used to treat varicose veins by injecting a liquid or foam sclerosant directly into the affected vein. The injection triggers a controlled inflammatory response, leading to fibrosis and vein occlusion. Over time, the treated vein gradually transforms into fibrous tissue and is reabsorbed by the body; however, in some cases, the vein may reopen. Potential complications of sclerotherapy include blood clot formation, skin discoloration, inflammation, ulceration, tissue damage, and adverse reactions to the sclerosant (de Ávila Oliveira et al. 2021). Sclerotherapy involves different types of sclerosants, each with a distinct mechanism of action. Hyperosmolar agents, such as hypertonic saline, cause cellular dehydration which leads to endothelial damage. These agents are often combined with lidocaine to minimize discomfort. Detergents, including polidocanol (Asclera, Varithena), sodium tetradecyl sulfate, and glycerin mixed with lidocaine and epinephrine, work by disrupting cell membranes and extracting proteins. These agents act within seconds but persist for hours.

Sclerotherapy can be performed using either liquid or foam sclerosants, depending on the vein size and physician preference. In the United States, only polidocanol and sodium tetradecyl sulfate are FDA-approved liquid sclerosants (Scovell 2026). Liquid sclerotherapy is primarily recommended for telangiectasias, while foam sclerotherapy is preferred for larger varicose veins. Concentrations of sclerosant used are determined by vessel type, diameter, and wall thickness (Tan et al. 2023). Foam is created by mixing a liquid sclerosant with air or CO₂/O₂, and there are two main types: physician-compounded foam and commercially manufactured foam, such as Varithena, a premixed foam sclerosant containing polidocanol endovenous microfoam (PEM).

PEM 1% (Varithena) was approved under a new drug application for the treatment of varicose veins in 2013. Efficacy data were derived from two randomized, blinded, multicenter studies (Todd & Wright 2014, 2015). One compared polidocanol at 0.5%, 1.0%, and 2.0% with endovenous placebo or a subtherapeutic dose of polidocanol foam. The primary endpoint was an improvement in symptoms at week 8, as measured by the Varicose Vein Symptoms Questionnaire. The improvement in symptoms was greater in the pooled polidocanol treatment group and in each of the individual dose-concentration groups compared with vehicle alone. Secondary and tertiary endpoints (appearance, duplex ultrasound response, and quality of life) were also significantly better in the polidocanol groups than in the control groups. King et al. (2015) confirmed VANISH-2 results in a multi-center parallel study of 284 subjects. Treatment with PEM 1% and PEM 2% resulted in similar side effects, was equally effective in improving symptoms and appearance, and had a similar duplex response rate, according to the authors.

Regulatory Status

Ultrasound-guided sclerotherapy (UGS) for varicose veins is classified as a procedure and thus not regulated by the U.S. Food and Drug Administration (FDA). However, the medications, devices, and diagnostic tools used in conjunction with UGS may be subject to FDA approval. The following have received FDA approval for the endovenous treatment of superficial vein reflux:

- Sodium tetradecyl sulfate injection (Sotradecol), a sclerosant, was FDA-approved via the New Drug Application (NDA) pathway, under NDA 040541 in 2004, for treating small, uncomplicated varicose veins in the lower extremities that exhibit simple dilation with competent valves.
- Polidocanol, another commonly used sclerosant, has been FDA-approved in two formulations.
 - Asclera was FDA-approved under NDA 021201 in 2010, for the treatment of uncomplicated spider veins (varicose veins 1 mm or less in diameter) and reticular veins (varicose veins between 1 and 3 mm in diameter) in the lower extremities.
 - Varithena (PEM 1%), a sclerosant microfoam formulation, was FDA-approved under NDA 205098 in 2013, for the treatment of incompetent great saphenous veins, accessory saphenous veins, and visible varicosities of the GSV system both above and below the knee.
- VenaSeal, a cyanoacrylate-based adhesive closure system, was FDA-approved in 2015, via the Premarket Approval (PMA) pathway under PMA P140018, product code PJQ, for the permanent closure of superficial varicose veins, including the great saphenous vein and other truncal veins, without the need for tumescent anesthesia or thermal ablation.

Compounded drug products are not FDA-approved and have not undergone the agency's premarket review for safety, efficacy, or manufacturing quality.

Molina Clinical Policy
Sclerotherapy and Adhesive Therapy for Varicose Veins
Policy No. 431

Last Approval: 04/08/2026
Next Review Due By: April 2027



RELATED POLICIES

Refer to MCG for other procedures related to varicose veins.

COVERAGE POLICY

Sclerotherapy or adhesive therapy for the treatment of symptomatic varicose veins or tributaries may be **considered medically necessary** when ALL the following criteria are met:

1. Documentation of ALL the following:
 - a. In-person physical examination confirming presence and severity of varicose veins
 - b. Measurements of the veins to be treated, taken with Member in standing position
 - c. Failure of properly fitted compression stocking therapy for 90 days, except in the presence of non-healing ulcers
 - d. Progress note including ALL the following:
 - i. Presence of ANY of the following:
 1. Ulceration secondary to stasis dermatitis
 2. Hemorrhage from a superficial varicosity
 3. Functional impairment due to venous insufficiency (e.g., burning, itching, cramping, or swelling) interfering with activities of daily living
 - ii. Persistence of symptoms despite weight loss, exercise regimens, and/or leg elevation
 - e. Doppler or Venous duplex report, performed within the past 6 months, along with documented note (e.g., consult, H&P) describing ALL the following:
 - i. Clinical, Etiological, Anatomical, and Pathophysiological (CEAP) Classification
 - ii. Venous Clinical Severity Score (VCSS)
 - iii. Reflux duration for Greater Saphenous Vein (GSV), Short Saphenous Vein (SSV), or accessory saphenous veins ≥ 0.5 seconds
 - f. *For Members with thrombophlebitis, dermatitis, ulcers, or bleeding that are unable to have a venous duplex report:* Pretreatment photographs of varicose veins are required to document the functional impairment. The photographs should accurately depict the clinical extent
 - g. *For vein incompetence or reflux present at the saphenofemoral junction or saphenopopliteal junction,* junctional reflux **MUST** be successfully treated via surgical ligation and stripping, endoluminal radiofrequency ablation, or endoluminal laser ablation prior to sclerotherapy
2. Absence of ALL the following contraindications:
 - a. Acute thrombotic occlusion (e.g., deep or superficial venous thrombosis, pulmonary embolism)
 - b. Acute superficial thrombophlebitis
 - c. Pregnancy or lactation (if the indication is urgent, interrupt lactation for 2–3 days)
 - d. Systemic and/or local infection in the region of sclerotherapy
 - e. Advanced peripheral arterial disease
 - f. Advanced collagen vascular disease
 - g. High risk of thromboembolism (e.g., known history of thromboembolic events, known severe thrombophilia, active cancer)
 - h. Long-term immobility or bedridden
3. **For Sclerotherapy:** Member meets ANY of the following indications for primary or secondary FDA approved liquid or foam sclerotherapy of incompetent saphenous or perforating veins, tributary or reticular varicose veins, and telangiectasias (CEAP C2 – C6):
 - a. Symptomatic great saphenous vein or accessory saphenous vein(s) ≥ 5 mm with reflux duration ≥ 500 ms and a VCSS ≥ 6
 - b. Symptomatic small saphenous vein, tributary vein(s), or other varicose vein(s) ≥ 3 mm with reflux duration ≥ 500 ms and a VCSS ≥ 6

Molina Clinical Policy
Sclerotherapy and Adhesive Therapy for Varicose Veins
Policy No. 431

Last Approval: 04/08/2026

Next Review Due By: April 2027



- c. Reticular vein(s), perforator vein(s), or telangiectasias $\leq 3.5\text{mm}$ resulting in symptomatic spontaneous or traumatic venous hemorrhage, or venous stasis ulceration
 - d. Perforator vein(s) $\geq 3.5\text{mm}$ with reflux duration $\geq 500\text{ms}$ and ANY of the following:
 - i. Vein(s) located beneath an open venous ulcer and truncal reflux has been corrected or will be treated concurrently
 - ii. Vein(s) located beneath a healed venous ulcer and truncal reflux has been corrected
4. **For Cyanoacrylate adhesive (e.g., VenaSeal) therapy:** Member meets EITHER of the following criteria for FDA approved medical adhesive therapy:
- a. Symptomatic great saphenous vein or accessory saphenous vein(s) $\geq 5\text{mm}$ with reflux duration $\geq 500\text{ms}$ and a VCSS ≥ 6
 - b. Symptomatic small saphenous vein, tributary vein(s), or other varicose vein(s) $\geq 3\text{mm}$ with reflux duration $\geq 500\text{ms}$ and a VCSS ≥ 6

Limitations and Exclusions

Medically necessary sclerotherapy for the treatment of varicose veins is restricted by the following quantity and dose limitations:

- 1. Quantity and code limitations: ONE sclerotherapy treatment session, **per leg**, per date of service
 - a. If one vein in one leg is treated, regardless of the number of injections, ONE unit of 36456 is appropriate per date of service
 - b. If multiple veins in one leg are treated, regardless of the number of injections, ONE unit of 36466 per leg per date of service is appropriate
 - c. Use of more than one unit of 36456 or 36466, or a combination of 36456 and 36466, per leg per date of service is not appropriate
- 2. A minimum of *six* weeks between treatment sessions **per leg**, as defined by the date on which the sclerotherapy treatment was performed
- 3. Up to THREE sclerotherapy treatment sessions **per leg** may be authorized within one rolling calendar year from the initial authorization
- 4. Sclerotherapy must NOT be performed earlier than three months after surgical ligation and stripping, endoluminal radiofrequency ablation, or endoluminal laser ablation of incompetent saphenous veins
- 5. Additional sclerotherapy sessions beyond the initial three sessions per leg within one rolling calendar year require submission of updated post-treatment clinical information for review, including a complete Venous Duplex report to demonstrate the result of intervention on the intervened vein(s) and presence of reflux on target vein(s) of the same extremity
- 6. Treatment of veins with a CEAP score of C0 or C1 in the absence of spontaneous and/or traumatic venous hemorrhage is considered cosmetic and therefore **not medically necessary**
- 7. Sclerotherapy used in conjunction with cyanoacrylate adhesion (VenaSeal Closure System), the COMPASS protocol, or a balloon catheter is considered **experimental, investigational, and unproven**
- 8. Cyanoacrylate adhesive (e.g., VenaSeal) therapy is considered **experimental, investigational, and unproven** in the treatment of perforator, reticular, and/or telangiectatic veins
- 9. Cyanoacrylate adhesive (e.g., VenaSeal) therapy is considered **experimental, investigational, and unproven** for repeat treatment of the same segment of vein previously closed with adhesive therapy unless venous reopening is documented

DOCUMENTATION REQUIREMENTS: Molina Healthcare reserves the right to require that additional documentation be made available as part of its coverage determination; quality improvement; and fraud; waste and abuse prevention processes. Documentation required may include, but is not limited to, patient records, test results and credentials of the provider ordering or performing a drug or service. Molina Healthcare may deny

Molina Clinical Policy

Sclerotherapy and Adhesive Therapy for Varicose Veins

Policy No. 431

Last Approval: 04/08/2026

Next Review Due By: April 2027



reimbursement or take additional appropriate action if the documentation provided does not support the initial determination that the drugs or services were medically necessary, not investigational, or experimental, and otherwise within the scope of benefits afforded to the member, and/or the documentation demonstrates a pattern of billing or other practice that is inappropriate or excessive.

SUMMARY OF MEDICAL EVIDENCE

Randomized Controlled Trials

Brittenden et al. (2019) published a randomized controlled trial (RCT) evaluating the clinical effectiveness of foam sclerotherapy, laser ablation, and surgery in 798 participants with primary varicose veins. The primary outcome measures at five years included disease-specific quality of life (Aberdeen Varicose Vein Questionnaire [AVVQ]), generic quality of life (EuroQol [EQ-5D] and Short Form-36 [SF-36]), and cost-effectiveness (cost per quality-adjusted life-year gained). Secondary outcomes included the extent of varicose veins, Venous Clinical Severity Score (VCSS), additional procedures, participant satisfaction, and treatment success assessed by duplex ultrasonography. Of the 798 participants, 75% completed quality-of-life questionnaires at five years. All treatment groups showed improvement from baseline, but AVVQ scores were significantly lower (indicating better outcomes) in the laser ablation and surgery groups compared to the foam sclerotherapy group ($p < 0.001$). No significant differences were observed among treatment groups in generic quality-of-life measures. At five years, 58% patients treated with laser ablation, 54% of surgery patients, and 47% of foam sclerotherapy patients reported having no varicose veins. Laser ablation had the highest probability (71.6%) of being cost-effective at a willingness-to-pay threshold of £20,000 (\$28,433) per quality-adjusted life-year. Surgery was preferred over foam sclerotherapy in 83.3% of cost-effectiveness comparisons. Study limitations included the lack of a sham procedure, unblinded participants, and missing data. Overall, the findings indicate that while all three treatments improve quality of life, laser ablation and surgery provide superior disease-specific outcomes compared to foam sclerotherapy, with laser ablation emerging as the most cost-effective option.

Systematic Reviews and Meta-Analyses

Chen et al. (2026) performed a systematic review and meta-analysis to evaluate the efficacy of Varithena with physician-compounded foams (PCFs) and other procedural/surgical interventions for truncal varicose veins. The review included 6 RCTs for a total of 1726 adult patients, primarily with Clinical, Etiological, Anatomical, and Pathophysiological (CEAP) class C2-C5 disease involving the great or small saphenous veins. Median follow-up across studies was 39 weeks. The primary outcome was complete vein occlusion, while secondary outcomes included adverse events, ulcer healing, and quality-of-life measures reported through the Aberdeen Varicose Vein Questionnaire/Severity Score, EQ-5D, or Chronic Venous Insufficiency Questionnaire (CIVIQ). Meta analysis found no significant difference in occlusion rates with PCF compared to Varithena (risk ratio [RR] 0.890, 95% confidence interval [CI] 0.739-1.073). Additionally, compared with Varithena, surgical ligation (RR 1.172, 95% CI 0.975-1.409) and endovenous laser ablation (EVLA) (RR 1.182, 95% CI, 0.965-1.447) were associated with higher occlusion rates; however, the difference was not statistically significant. There were no statistically significant differences in quality-of-life outcomes between treatments, but some studies reported worse disease-specific quality-of-life scores in foam-treated patients. Adverse events were not reported consistently throughout the studies and therefore only 4 RCTs were selected for meta-analysis. Overall, there were no statistically significant differences in adverse event rates between Varithena, PCF, and surgery; however, endovenous laser ablation was associated with significantly lower adverse events when compared to Varithena (RR 0.178, 95% CI 0.033-0.966). Limitations include significant heterogeneity between studies and insufficient data and quality for several outcomes, which limit comparisons between treatment modalities. Heterogeneity is influenced by operator technique variability with PCF (e.g., lack of consistent reporting of air/CO₂ volumes and concentrations, mixing techniques and drug amounts used). The authors also noted that reported occlusion rates may not accurately reflect recurrence rates for patients between treatment modalities. The authors concluded that in patients with truncal varices, Varithena did not show superiority to PCF. Endovenous laser ablation and surgical removal of truncal varices had higher rates of occlusion, which is consistent with the current literature and international guideline recommendations.

Alozai et al. (2022) conducted a systematic review and meta-analysis to evaluate and compare treatment outcomes for anterior accessory saphenous vein (AASV) incompetence. The primary outcome was anatomic success, defined as AASV occlusion, with secondary outcomes including pain during and after treatment, venous clinical severity scores, quality of life, esthetic results, time to return to daily activities, and complications. A total of 16 articles were included, reporting on 609 cases of treated AASVs. The pooled anatomic success rates were 91.8% for EVLA and radiofrequency ablation (RFA), 93.6% for cyanoacrylate closure, and 79.8% for sclerotherapy. Non-pooled success rates included 97.9% for phlebectomy and 82% for Conservative Hemodynamic Cure for Insufficient Venous

Molina Clinical Policy

Sclerotherapy and Adhesive Therapy for Varicose Veins

Policy No. 431

Last Approval: 04/08/2026

Next Review Due By: April 2027



Abnormalities (CHIVA). Complication rates varied, with paresthesia occurring in 0.7% of EVLA patients, phlebitis in 2.6% of RFA cases, 27% after sclerotherapy, and 12% following phlebectomy. No cases of deep venous thrombosis or skin burns were reported. The findings suggest that AASV incompetence can be effectively treated with endovenous thermal ablation and cyanoacrylate, with no clear advantage of EVLA over RFA. Phlebectomy appears promising for patients with a competent saphenofemoral junction, whereas sclerotherapy and CHIVA demonstrated lower success rates.

de Ávila Oliveira et al. (2021) published a Cochrane review evaluating the effectiveness and safety of injection sclerotherapy for varicose veins, analyzing 28 studies with 4,278 participants. Primary outcomes measured included cosmetic appearance, complications, residual varicose veins, quality of life, symptom persistence, and recurrence. Compared to placebo, foam sclerotherapy may improve cosmetic appearance, reduce residual varicose veins, and enhance quality of life, but may slightly increase the risk of deep vein thrombosis. No clear differences were found between different foam concentrations in cosmetic outcomes or thromboembolic complications, though higher concentrations of polidocanol foam may slightly reduce residual varicose veins, and two RCTs suggested improved VCSS with increasing foam concentration. Compared to liquid sclerotherapy, foam may provide greater reduction in residual varicose veins, though no significant differences were found in cosmetic appearance or recurrence rates. Comparisons between sclerotherapy using different substances were inconclusive due to data heterogeneity. While sclerotherapy appears effective for varicose veins, further high-quality trials with standardized sclerosant doses, core outcome sets, and measurement time points are needed to improve the certainty of the evidence.

Whing et al. (2021) published a Cochrane review assessing the effectiveness of various treatments for great saphenous vein varicosities, including EVLA, RFA, endovenous steam ablation, ultrasound-guided foam sclerotherapy (UGFS), cyanoacrylate glue, mechanochemical ablation (MOCA), and high ligation and stripping (HL/S). The review included 24 RCTs with 5,135 participants, with follow-up periods ranging from five weeks to eight years. Comparisons revealed that technical success rates were similar among treatments, though EVLA showed advantages over UGFS and HL/S, and HL/S performed better than UGFS. Recurrence rates were comparable, except for a potential long-term benefit of RFA over EVLA and HL/S. Complications were low, though variations in reporting limited conclusions. Quality of life outcomes were also comparable, though studies used different assessment tools. Limitations included small sample sizes for some comparisons and inconsistent outcome definitions. Future research should standardize reporting and further evaluate long-term outcomes across treatment modalities.

Knight Nee Shingler et al. (2021) published a Cochrane review evaluating the effectiveness of graduated compression stockings as the initial or sole treatment for varicose veins in patients without healed or active venous ulceration (CEAP class C2-C4). The review included 13 RCTs for a total of 1021 participants, with studies comparing stockings to placebo stockings, no treatment, or against different stocking types or pressures. Outcomes assessed included symptom improvement measured by VAS or other validated scales, physiological measures (e.g., ankle circumference, edema, duplex findings), complications, patient compliance, comfort, and quality of life. The overall certainty of evidence across all outcomes was rated as low to very low. This was primarily due to heterogeneity, small sample sizes, and methodological limitations. Overall, while RCTs commonly reported subjective symptom improvement with stocking use, improvements were infrequently analyzed by a direct comparison between randomized groups, which introduced risk of bias. In a double-blind, placebo RCT by Kakkos et al. (2018), graduated elastic compression stockings were effective in alleviating symptoms, particularly pain or arching, after just 1 week of use when compared with placebo stockings (VAS score 1.7 ± 3.0 vs. 4.5 ± 2.8 for placebo, $p = .02$). Overall, the authors of the Cochrane review concluded that there is insufficient high-certainty evidence to determine whether compression stockings are effective as the sole and initial treatment for varicose veins without ulcerations. However, compression therapy remains to be widely used as a first-line, conservative management approach in clinical practice.

National/Specialty Organizations

The **American Vein and Lymphatic Society (AVLS)**, formerly known as the American College of Phlebology (ACP), published 2016 guidelines based on a review of the available literature and expert consensus on the clinical impact and treatment of incompetent accessory saphenous veins. Using a consensus-based approach, the AVLS recommends that patients with symptomatic incompetence of the great saphenous, small saphenous, and the anterior and posterior accessory of the great saphenous veins undergo endovenous thermal ablation (laser or radiofrequency), a GRADE 1B recommendation (strong recommendation, moderate quality of evidence). Mechanical/chemical ablation may also be used to treat truncal venous reflux, a GRADE 2B recommendation (weak recommendation, moderate-

Molina Clinical Policy

Sclerotherapy and Adhesive Therapy for Varicose Veins

Policy No. 431

Last Approval: 04/08/2026

Next Review Due By: April 2027



quality evidence). The AVLS recommends that non-visible symptomatic tributary veins be treated using ultrasound-guided liquid sclerotherapy or foam chemical ablation, and that visible, symptomatic tributary veins be treated with stab phlebectomy, liquid sclerotherapy, or foam chemical ablation, GRADE 1B recommendations. For incompetent, perforating veins located beneath a healed or open venous ulcer, thermal ablation, ligation, or sclerotherapy is recommended. For initial therapy, the AVLS issues a Grade 1A recommendation (strong recommendation, high-quality evidence), stating that while compression therapy effectively manages symptoms, definitive treatment should be provided when a correctable source of reflux is present. If a definitive treatment is available, compression therapy alone is not advised. The AVLS recommends that all patients being considered for treatment must have a duplex ultrasound of the superficial venous system (AVLS 2016).

The **European Society of Vascular Surgery (ESVS)** (De Maeseneer et al. 2022) Clinical Practice Guidelines on the Management of Chronic Venous Disease of the Lower Limbs, specifically notes “for patients with chronic venous disease requiring treatment of varicose tributaries, ambulatory phlebectomy, ultrasound-guided foam sclerotherapy, or a combination of both is recommended.”

Additionally, a European guideline developed on behalf of 23 European phenological societies, recommends sclerotherapy for various chronic venous disorders, including incompetent saphenous veins, tributary varicose veins, and incompetent perforating veins. It is also recommended for reticular varicose veins, telangiectasias, recurrent varicose veins after treatment, varicose veins of pelvic origin, varicose veins near leg ulcers, and venous malformations. For C1 disease, liquid sclerotherapy is preferred, though foam may also be used. While thermal ablation and surgery are well-established treatments for incompetent saphenous veins, foam sclerotherapy remains a viable alternative. Additionally, duplex ultrasound is recommended both before sclerotherapy to assess venous incompetence and during the procedure to guide injection placement (Rabe et al. 2014).

The **Society for Vascular Surgery (SVS)**, **American Venous Forum (AVF)**, and **AVLS** developed clinical practice guidelines for the management of varicose veins of the lower extremities. The guidelines recommend the following (Gloviczki et al. 2023, 2024):

- The use of the 2020 updated CEAP classification system for chronic venous disorders.
- The use of the revised VCSS for patients with chronic venous disorders for grading clinical severity and for assessment of post treatment outcome.
- Doppler ultrasound scanning is recommended as the diagnostic choice to evaluate for venous reflux in patients with chronic venous disease of the lower extremities.
- Reflux is defined as a minimum value > 500 ms of reversed flow in the superficial truncal veins (great saphenous vein [GSV], small saphenous vein [SSV], anterior accessory GSV [AAGSV], and posterior accessory GSV [PAGSV]) and in the tibial, deep femoral, and perforating veins.
- Axial reflux of the GSV is defined as uninterrupted retrograde venous flow from the groin to the upper calf. Axial reflux in the SSV is defined as being from the knee to the ankle. Axial reflux in the AAGSV and PAGSV is retrograde flow between two measurements, at least five cm apart. Retrograde flow can occur in the superficial or deep veins, with or without perforating veins. Junctional reflux is limited to the saphenofemoral or saphenopopliteal junction. Segmental reflux occurs in only a portion of a superficial or deep truncal vein.
- ‘Pathologic’ perforating veins are defined as those with an outward flow duration of > 500 ms and a diameter of > 3.5 mm on Doppler ultrasound scanning (CEAP clinical class C2).
- For patients with symptomatic varicose veins and axial reflux in the superficial truncal veins, we suggest compression therapy for primary treatment if the patient's ambulatory status and/or underlying medical conditions warrant a conservative approach, or if the patient prefers conservative treatment for either a trial period or definitive management.
- For patients with symptomatic varicose veins and axial reflux in the GSV or SSV who are candidates for intervention, we recommend superficial venous intervention over long-term compression stockings.
- For patients with symptomatic varicose veins and axial reflux in the AAGSV or PAGSV, who are candidates for intervention, we suggest superficial venous intervention over long-term compression stockings.
- In patients with symptomatic varicose veins who are candidates for endovenous therapy and wish to proceed with treatment, we suggest against a 3-month trial of compression therapy before intervention.
- For patients with symptomatic varicose veins and axial reflux in the GSV who place a high priority on the long-term outcomes of treatment (quality of life and recurrence), we suggest treatment with EVLA, RFA, or high

Molina Clinical Policy

Sclerotherapy and Adhesive Therapy for Varicose Veins

Policy No. 431

Last Approval: 04/08/2026

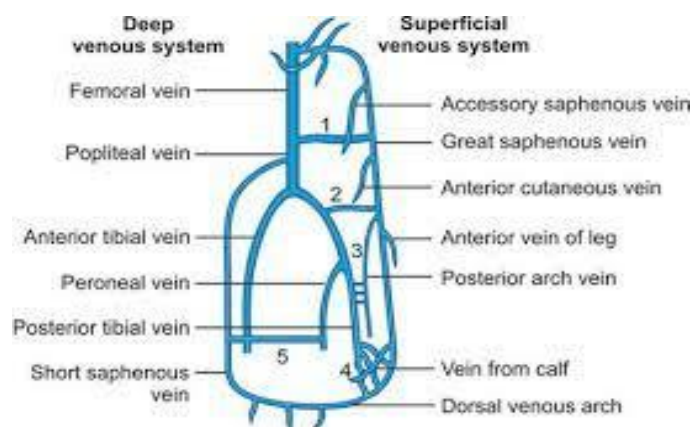
Next Review Due By: April 2027



ligation and stripping over physician-compounded ultrasound-guided foam sclerotherapy, because of long-term improvement of quality of life and reduced recurrence.

- For patients with symptomatic telangiectasias and reticular veins, we recommend liquid or foam sclerotherapy.
- For treatment of symptomatic varicose tributaries, we recommend mini-phlebectomy or ultrasound-guided sclerotherapy using PCF or polidocanol endovenous microfoam.
- For patients with symptomatic reflux in the GSV or SSV and associated varicosities, we recommend ablation of the refluxing venous trunk and concomitant phlebectomy or ultrasound-guided foam sclerotherapy of the varicosities with PCF or polidocanol endovenous microfoam.
- We recommend against treatment incompetent perforating veins at the same time as initial saphenous vein ablation in patients with varicose veins (CEAP class C2) and significant symptomatic axial reflux of the GSV or SSV.

SUPPLEMENTAL INFORMATION



Varicose Vein or Varicosity: Veins that are abnormally swollen or enlarged due to venous wall weakness. Measured in an upright position these veins are 3 mm or greater in diameter.

Superficial Veins: Veins that run in the subcutaneous tissue in the lower limbs; the greater saphenous vein (GSV) and the short saphenous vein (SSV) are the two major superficial veins.

Reticular Vein: Dilated bluish subdermal vein, generally 1 mm to less than 3 mm in diameter and usually tortuous.

Telangiectasia: A type of varicose vein, also known as spider veins, that are small bluish-purple veins and usually found in clusters on the legs.

Tributary Vein: A superficial vein branch that flows into larger veins.

Saphenous Veins

- Accessory Saphenous Veins: A vein running in the thigh parallel to the great and small saphenous veins.
- Greater Saphenous Vein: The longest vein in the body, extending from the dorsum of the foot to just below the inguinal ligament, where it opens into the femoral vein.
- Short Saphenous Vein: The vein that continues the marginal vein from behind the malleolus and passes up the back of the leg to the knee joint, where it opens into the popliteal vein. Also known as the lesser saphenous vein.

Clinical, Etiological, Anatomical, Pathophysiological (CEAP) Classification (Lurie et al. 2020)

Classification for chronic venous disorders is based on clinical severity (C), etiology (E), anatomy (A), and pathophysiology (P) to improve the accuracy of the diagnosis (CEAP):

Molina Clinical Policy
Sclerotherapy and Adhesive Therapy for Varicose Veins
Policy No. 431

Last Approval: 04/08/2026
 Next Review Due By: April 2027



Clinical classification	
C0	No visible or palpable signs of disease
C1	Telangiectasias or reticular veins
C2	Varicose veins
C3	Edema
C4a	Pigmentation or eczema
C4b	Lipodermatosclerosis or atrophic blanche
C5	Healed venous ulcer
C6	Active venous ulcer
S	Symptomatic, including ache, pain, tightness, skin irritation, heaviness, muscle cramps, and other complaints attributable to venous dysfunction
A	Asymptomatic
Etiologic classification	
Ec	Congenital
Ep	Primary
Es	Secondary (post-thrombotic)
En	No venous cause identified
Anatomic classification	
As	Superficial veins
Ap	Perforator veins
Ad	Deep veins
An	No venous location identified
Pathophysiologic	
Pr	Reflux
Po	Obstruction
Pr, o	Reflux and obstruction
Pn	No venous pathophysiology identifiable

Venous Clinical Severity Score (VCSS) is an assessment tool used to complement the CEAP scoring system of varicose veins. This tool uses both physician-determined, and patient-reported elements, which include ten parameters graded from zero to three depending on severity (pain, varicose veins, venous edema, pigmentation, inflammation, induration, number of active ulcers, duration of active ulcers, size of active ulcers, and compliance with compression therapy) to establish a baseline against which to compare progression over time and/or effects of intervention (UpToDate 2023).

Category	None (0)	Mild (1)	Moderate (2)	Severe (3)
Pain or Other Discomfort	None	Occasional pain or discomfort that does not restrict daily activities	Daily pain or discomfort that interferes with, but does not prevent, regular daily activities	Daily pain or discomfort that limits most regular daily activities
Varicose Veins	None	Few, scattered, varicosities that are confined to branch veins or clusters. Includes "corona phlebectatica" (ankle flare), defined as greater than 5 blue telangiectasia at the inner or sometimes the outer edge of the foot	Multiple varicosities that are confined to the calf or the thigh	Multiple varicosities that involve both the calf and the thigh
Venous Edema	None	Edema that is limited to the foot and ankle	Edema that extends above the ankle but below the knee	Edema that extends to the knee or above
Skin Pigmentation	None, or focal pigmentation that is confined to the skin over varicose veins	Pigmentation that is limited to the perimalleolar area	Diffuse pigmentation that involves the lower third of the calf	Diffuse pigmentation that involves more than the lower third of the calf
Induration	None	Induration that is limited to the peri-malleolar area	Induration that involves the lower third of the calf	Induration that involves more than the lower third of the calf
Active Ulcer Number	None	One Ulcer	Two Ulcers	Three Ulcers
Active Ulcer Duration	No active ulcers	Ulceration present for less than 3 months	Ulceration present for 3-12 months	Ulceration present for greater than 12 months
Active Ulcer Size	No active ulcer	Ulcer less than 2 cm in diameter	Ulcer 2-6 cm in diameter	Ulcer greater than 6 cm in diameter

Molina Clinical Policy
Sclerotherapy and Adhesive Therapy for Varicose Veins
Policy No. 431

Last Approval: 04/08/2026
 Next Review Due By: April 2027



Use of Compression Therapy (based on compliance)	Not used	Intermittent use	Wears stockings most days	Full compliance with stockings
--	----------	------------------	---------------------------	--------------------------------

CODING & BILLING INFORMATION

CPT (Current Procedural Terminology)

Code	Description
36465	Injection of non-compounded foam sclerosant with ultrasound compression maneuvers to guide dispersion of the injectate, inclusive of all imaging guidance and monitoring; single incompetent extremity truncal vein (e.g., great saphenous vein, accessory saphenous vein)
36466	Injection of non-compounded foam sclerosant with ultrasound compression maneuvers to guide dispersion of the injectate, inclusive of all imaging guidance and monitoring; multiple incompetent truncal veins (e.g., great saphenous vein, accessory saphenous vein), same leg
36468	Injection(s) of sclerosant for spider veins (telangiectasia), limb or trunk
36470	Injection of sclerosant; single incompetent vein (other than telangiectasia)
36471	Injection of sclerosant; multiple incompetent veins (other than telangiectasia), same leg
36482	Endovenous ablation therapy of incompetent vein, extremity, by transcatheter delivery of a chemical adhesive (e.g., cyanoacrylate) remote from the access site, inclusive of all imaging guidance and monitoring, percutaneous; first vein treated
36483	Endovenous ablation therapy of incompetent vein, extremity, by transcatheter delivery of a chemical adhesive (e.g., cyanoacrylate) remote from the access site, inclusive of all imaging guidance and monitoring, percutaneous; subsequent vein(s) treated in a single extremity, each through separate access sites (List separately in addition to code for primary procedure)

CODING DISCLAIMER: Codes listed in this policy are for reference purposes only and may not be all-inclusive. Deleted codes and codes which are not effective at the time the service is rendered may not be eligible for reimbursement. Listing of a service or device code in this policy does not guarantee coverage. Coverage is determined by the benefit document. Molina adheres to Current Procedural Terminology (CPT®), a registered trademark of the American Medical Association (AMA). All CPT codes and descriptions are copyrighted by the AMA; this information is included for informational purposes only. Providers and facilities are expected to utilize industry standard coding practices for all submissions. When improper billing and coding is not followed, Molina has the right to reject/deny the claim and recover claim payment(s). Due to changing industry practices, Molina reserves the right to revise this policy as needed.

APPROVAL HISTORY

04/08/2026	Policy revised. Added quantity and code limitations. Clarified that an in-person physical exam is required. IRO peer reviewed on March 30, 2026 by a practicing physician board certified in vascular surgery.
12/10/2025	Policy updated to address chemical adhesive (e.g., VenaSeal) therapy. Annual review date remains April 2026.
04/09/2025	Policy reviewed. Included requirement for physical examination, measurements of veins, lifestyle changes documentation, and requirement for interventions for larger incompetent veins prior to sclerotherapy in coverage criteria. Clarified clinically significant measurements and CEAP scores. Included acute pulmonary embolism in contraindications. Removed "poor general state of health" and relative contraindications from limitations section. Title changed to "Sclerotherapy for Varicose Veins". IRO reviewed on April 1, 2025, by practicing physician board certified in Vascular Surgery.
04/10/2024	Policy reviewed, no changes to coverage criteria. Summary of Medical Evidence and References updated.
10/12/2023	Removed reference to "Continuation to Treatment" criteria.
04/20/2023	New policy. IRO Peer Review completed on 3/17/2023 by a practicing physician board-certified in Vascular Surgery.

REFERENCES

- American Vein and Lymphatic Society (AVLS). Practice guidelines: Superficial venous disease rev020316. Published February 3, 2016. Accessed March 24, 2026. <https://www.myavls.org/member-resources/clinical-guidelines.html>
- Alozai T, Huizing E, Schreve MA, et al. A systematic review and meta-analysis of treatment modalities for anterior accessory saphenous vein insufficiency. *Phlebology*. 2022 Apr;37(3):165-179. doi: 10.1177/02683555211060998. Epub 2021 Dec 30. PMID: 34965757.
- Beneat A, Oropallo A. Sclerotherapy. In: StatPearls [Internet]. Treasure Island (FL): StatPearls Publishing. Updated January 11, 2024. Accessed March 18, 2026. <https://www.ncbi.nlm.nih.gov/books/NBK599526/>
- Brittenden J, Cooper D, Dimitrova M, et al. Five-year outcomes of a randomized trial of treatments for varicose veins. *N Engl J Med*. 2019 Sep 5;381(10):912-922. doi: 10.1056/NEJMoa1805186. PMID: 31483962.

Molina Clinical Policy

Sclerotherapy and Adhesive Therapy for Varicose Veins

Policy No. 431

Last Approval: 04/08/2026

Next Review Due By: April 2027



5. Chen R, Soh CL, Salih M, Tan M, Turner B, Onida S, et al. Comparison of polidocanol endovenous microfoam (Varithena) to physician-compounded foam in sclerotherapy treatment of truncal varicosities: A systematic review and network meta-analysis. *J Vasc Surg Venous Lymphat Disord.* 2026 Feb 26;14(4):102460. doi: 10.1016/j.jvsv.2026.102460. Epub ahead of print. PMID: 41763540.
6. de Ávila Oliveira R, Riera R, Vasconcelos V, et al. Injection sclerotherapy for varicose veins. *Cochrane Database Syst Rev.* 2021 Dec 10;12(12):CD001732. doi: 10.1002/14651858.CD001732.pub3. PMID: 34883526; PMCID: PMC8660237.
7. De Maeseener MG, Kakkos SK, Aherne T, et al. ME. Editor's Choice - European Society for Vascular Surgery (ESVS) 2022 Clinical practice guidelines on the management of chronic venous disease of the lower limbs. *Eur J Vasc Endovasc Surg.* 2022 Feb;63(2):184-267. doi: 10.1016/j.ejvs.2021.12.024. Epub 2022 Jan 11. Erratum in: *Eur J Vasc Endovasc Surg.* 2022 Aug-Sep;64(2-3):284-285. PMID: 35027279.
8. Gloviczki P., Lawrence P.F., Wasan S.M., et al. The 2022 society for vascular surgery, American venous Forum, and American vein and lymphatic society clinical practice guidelines for the management of varicose veins of the lower extremities. Part I. Duplex scanning and treatment of superficial truncal reflux: endorsed by the society for vascular medicine and the international union of phlebology. *J Vasc Surg Venous Lymphat Disord.* 2023;11:231–261.e6. doi: 10.1016/j.jvsv.2022.09.004.
9. Gloviczki P, Lawrence PF, Wasan SM, et al. The 2023 Society for Vascular Surgery, American Venous Forum, and American Vein and Lymphatic Society clinical practice guidelines for the management of varicose veins of the lower extremities. Part II: Endorsed by the Society of Interventional Radiology and the Society for Vascular Medicine. *J Vasc Surg Venous Lymphat Disord.* 2024 Jan;12(1):101670. doi: 10.1016/j.jvsv.2023.08.011. Epub 2023 Aug 29. Erratum in: *J Vasc Surg Venous Lymphat Disord.* 2024 Sep;12(5):101923. doi: 10.1016/j.jvsv.2024.101923. PMID: 37652254; PMCID: PMC11523430.
10. Kakkos SK, Timpilis M, Patrinos P, Nikolakopoulos KM, Papageorgopoulou CP, Kouri AK, et al. Acute Effects of Graduated Elastic Compression Stockings in Patients with Symptomatic Varicose Veins: A Randomised Double Blind Placebo Controlled Trial. *Eur J Vasc Endovasc Surg.* 2018 Jan;55(1):118-125. doi: 10.1016/j.ejvs.2017.10.004. Epub 2017 Nov 10. PMID: 29129457.
11. King JT, O'Byrne M, Vasquez M, et al. Treatment of truncal incompetence and varicose veins with a single administration of a new polidocanol endovenous microfoam preparation improves symptoms and appearance. *Eur J Vasc Endovasc Surg.* 2015 Dec;50(6):784-93. doi: 10.1016/j.ejvs.2015.06.111. Epub 2015 Sep 16. PMID: 26384639.
12. Knight Nee Shingler SL, Robertson L, Stewart M. Graduated compression stockings for the initial treatment of varicose veins in people without venous ulceration. *Cochrane Database Syst Rev.* 2021 Jul 16;7(7):CD008819. doi: 10.1002/14651858.CD008819.pub4. PMID: 34271595; PMCID: PMC8407251.
13. Lurie F, Passman M, Meisner M, et al. The 2020 update of the CEAP classification system and reporting standards. *J Vasc Surg Venous Lymphat Disord.* 2020 May;8(3):342-352. doi: 10.1016/j.jvsv.2019.12.075. Epub 2020 Feb 27. Erratum in: *J Vasc Surg Venous Lymphat Disord.* 2021 Jan;9(1):288. PMID: 32113854.
14. Mathes B. Diagnostic evaluation of lower extremity chronic venous disease. Updated October 16, 2025. Literature review current through February 2026. Accessed March 18, 2026. <https://www.uptodate.com>.
15. Rabe E, Pannier F; for the Guideline Group. Indications, contraindications and performance: European Guidelines for Sclerotherapy in Chronic Venous Disorders. *Phlebology.* 2014 May;29(1 suppl):26-33. doi: 10.1177/0268355514528127. Epub 2014 May 19. PMID: 24843082.
16. Raetz J, Wilson M, Collins K. Varicose Veins: Diagnosis and Treatment. *Am Fam Physician.* 2019 Jun 1;99(11):682-688. PMID: 31150188.
17. Scovell S. Injection sclerotherapy techniques for the treatment of telangiectasias, reticular veins, and small varicose veins. Updated January 21, 2026. Literature review current through February 2026. Accessed March 18, 2026. <https://www.uptodate.com>.
18. Tan M, Moreno HB, Bechter-Hugl B, Giancesini S, Connor D, Parsi K, Davies AH. Sclerotherapy: Indications and safety volumes. *Phlebology.* 2024 Mar;39(2):135-138. doi: 10.1177/02683555231211092. Epub 2023 Oct 29. PMID: 37899570; PMCID: PMC10877989.
19. Todd KL 3rd, Wright DJ; VANISH-2 Investigator Group. The VANISH-2 study: A randomized, blinded, multicenter study to evaluate the efficacy and safety of polidocanol endovenous microfoam 0.5% and 1.0% compared with placebo for the treatment of saphenofemoral junction incompetence. *Phlebology.* 2014 Oct;29(9):608-18. doi: 10.1177/0268355513497709. Epub 2013 Jul 17. PMID: 23864535.
20. Todd KL 3rd, Wright DJ; VANISH-2 Investigator Group. Durability of treatment effect with polidocanol endovenous microfoam on varicose vein symptoms and appearance (VANISH-2). *J Vasc Surg Venous Lymphat Disord.* 2015 Jul;3(3):258-264.e1. doi: 10.1016/j.jvsv.2015.03.003. Epub 2015 May 6. PMID: 26992303.
21. United States Food and Drug Administration (FDA). Drugs@FDA: ASCLERA. NDA: 021201. Accessed March 18, 2026. <https://www.fda.gov>.
22. United States Food and Drug Administration (FDA). Drugs@FDA: SOTRADECOL. NDA: 040541. Accessed March 18, 2026. <https://www.fda.gov>.
23. United States Food and Drug Administration (FDA). Drugs@FDA: VARITHENA. NDA: 205098. Accessed March 18, 2026. <https://www.fda.gov>.
24. United States Food and Drug Administration (FDA). Premarket approval (PMA): VENASEAL CLOSURE SYSTEM (multiple approvals). Product code PJQ. PMA: P140018. Accessed March 18, 2026. <https://www.fda.gov>.
25. Whing J, Nandhra S, Nesbitt C, et al. Interventions for great saphenous vein incompetence. *Cochrane Database Syst Rev.* 2021 Aug 11;8(8):CD005624. doi: 10.1002/14651858.CD005624.pub4. PMID: 34378180; PMCID: PMC8407488.